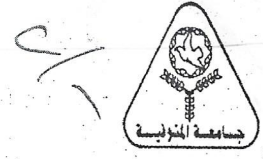




**Menoufia University**  
**Faculty of Veterinary Medicine**  
**General applied and comparative anatomy exam**  
**Second Year,**



Date: 21.2.2021

time allowed: 2 Hours

A. Liver	B. Omasum	C. Abdominal wall	D. Abomasum
28- The hepatogastric ligament of dog attached liver to.....of stomach			
A. Greater curvature	B. Lesser curvature	C. Parietal surface	D. Visceral surface
29- In monolocular stomach the part bulges above the carida is the .....			
A. Body	B. Fundus	C. Pyloric region	D. Cardiac region
30- The cardiac gland region is very large in.....			
A. Horse	B. Dog	C. Pig	D. Ox
31- The external landmark between cecum and ascending colon of sheep is			
A. Ileum	B. Ascending duodenum	C. Descending duodenum	D. Descending colon
E. Para-anal sinuses is a feature of the large intestine of .....			
A. horse	B. ox	C. sheep	D. dog
32- The nostril is slit like opening with closer ventral angle in.....			
A. Horse	B. Ox	C. Dog	D. Sheep
33- Lateral accessory nasal cartilages are attached to ventral lateral cartilages in .....			
A. Pig	B. Dog	C. Horse	D. Sheep
34- The sinus nasal meatus is the..... meatus			
A. Dorsal	B. Ventral	C. Middle	D. Common
35- All the present cartilages of larynx are elastic cartilage except.....			
A. Epiglottis	B. Cuneiform	C. Cricoid	D. Epiglottis
36- All structures of thoracic cavity located within mediastinum except.....			
A. Lungs	B. Right phrenic N	C. Caudal vena cava	D. All of them
37- The vocal cord is attached to the vocal process of .....			
A. Epiglottis	B. Thyroid	C. Cricoid	D. Arytenoid
38- The petiolus is the main feature of.....cartilage			
A. Epiglottis	B. Thyroid	C. Cricoid	D. Arytenoid
39- The total number of hiluses of both right and left lung of ox is .....			
A. 1	B. 2	C. 3	D. 4
40- The right principle bronchus of ox is divided into.....lobar bronchi			