

EVALUATION OF PLATE-PIN CONSTRUCT FOR REPAIR OF DIAPHYSEAL TIBIAL FRACTURES IN DOGS

Alaa, Samy; Mosbah, E.; Karrouf, G. I. A. and Zaghloul, A. E.

Dept. of Surgery, Anaesthesiology and Radiology, Fac. of Vet. Medicine, Mansoura University.

ABSTRACT

Plate-pin constructs were evaluated clinically and radiographically for repair of diaphyseal tibial fractures in 10 adult apparently healthy mongrel dogs of both sexes with an average age of 2 years and weighted about 20 kg B.W where fractures were traumatically induced. The fractured tibias were stabilized by plate-pin constructs using 3.5 mm bone plates (dynamic compression plates or semi-tubular plates) with steinmann pins which occupied 35 to 40% of the medullary cavity. Bone plates were applied medially and fixed with both mono-cortical and bi-cortical screws. Postoperative data obtained by evaluating radiographs and documented clinical findings. Eight dogs showed normal clinical and radiographic bone healing.

The study suggested that the plate-pin construct has been considered as a suitable and stable method for treatment of diaphyseal tibial fractures with high rates of fracture healing.

INTRODUCTION

Bone fractures constitute a major problem in small animal practice particularly in dogs. Fractures of the tibia are chosen because of their relatively high incidence and may occur at any level. They comprise about 21% of long bone and 11.7% of total limb fractures. Moreover, they represent serious injuries, take a long time to heal and historically have a very poor outcome (Caudel & Stern, 1987; Johnson et al., 1994; Tornetta et al., 1994; Singer & Kellam, 1995; Gorse, 1998 and Harason, 2003).

Open reduction and internal fixation of fractures (ORIF) is widely used in veterinary orthopedics. However, the principles

of ORIF continue to evolve with the introduction of newer implants and methods in attempts to improve the results. Proper implant selection and surgical technique are critical to a successful outcome (Perren, 1991; Gautirer et al., 1992 and Stiffler, 2004).

There have been changes in the management of diaphyseal fractures, toward less rigid fixation techniques which result in bridging the fracture gap without reconstruction of the fracture fragments by using either buttress plate, plate-pin construct, external skeletal fixator or interlocking nail (Aron et al., 1995; Braden et al., 1995; Johnson et al., 1998 and Palmer, 1999).

The plate-pin construct has the additional biological function to bridge the major fracture fragments without the need for attempts to reduce and stabilize adjacent small fragments. Bridging osteosynthesis has been shown to result in faster healing as well as quicker application for the repair of highly comminuted fractures compared with fragment reconstruction and bone plate application (Hulse & Johnson, 1997 and Im & Tae, 2005).

The increased importance of this branch of surgery prompted the planning of the present work by evaluation of the use of plate-pin constructs for repair of diaphyseal tibial fractures in dogs in addition of assessment of bone healing clinically and radiographically.

MATERIALS AND METHODS

The present study was conducted on a total number of 10 adult apparently healthy mongrel dogs of both sexes with an average age of 2 years and weighted about 20 kg B.W. These animals were divided into two groups according to the type of the implants.

- a) **Group I (5) dogs:** application of plate-pin constructs using dynamic compression plate (DCP) and Steinmann pin.
- b) **Group II (5) dogs:** application of plate-pin constructs using semi-tubular plate and Steinmann pin.

All dogs were injected 30 minutes prior to start of surgery with Cephadrine,* at a dose of 50 mg/kg B.W. I/V; Gentamicin, ** at a dose of 4 mg/kg B.W. I/V; and Meloxicam*** at a dose of 0.125 mg/kg B.W. I/M. Anesthesia was obtained by intravenous injection of Atropine sulphate 0.1%**** at a dose of 0.1 mg/

kg. B.W. I/M, followed by intravenous injection of Xylazine Hcl***** 2% at a dose of 1mg/kg B.W. before anesthetic induction. Thiopental sodium***** was intravenously injected at 2.5% concentration for induction and maintenance of general anesthesia.

Preoperative antero-posterior and medial radiographs of the intended bone were taken for each dog. Standard surgical approaches to the involved bone were carried out for application of plate-pin constructs according to Pflummatt (1993) and Hickman et al. (1995). Steinmann intramedullary pin (IMP) of appropriate length and diameter was inserted initially via a normograde fashion, followed by application of bone plates (Fig. 1). Light compression bandage was applied for one week.

Postoperatively, animals' movements were kept restricted in clean dry cages. Preoperative antibiotics and anti inflammatory were continued for five successive days. Postoperatively, data obtained by evaluating radiographs and documented clinical findings were recorded at 1, 2, 3 and 4 months after surgery.

RESULTS

Following induction of fractures in tibia and fibula, internal fixations were accomplished by plate-pin constructs. Steinmann pins provided axial alignments that offered partial stability for application of 3.5 mm bone plates (DCP or semi-tubular plate). Postoperative radiographs revealed proper fracture alignment (Fig. 2).

One week postoperatively, all dogs were ambulatory partially weight bearing of the

operative limbs during stride and showed difficulties in succession. Seroma formation was noticed at the fourth postoperative day and wound breakdown was occurred in one dog with DC plate-pin construct.

One month after surgery, 8 dogs landed well in all directions without lameness. Radiographs revealed beginning of healing process from marginal site of the defect as the fracture lines were ill distinct but not completely disappeared. No visible callus was noticed (Fig.3). One of these dogs with DC plate-pin construct showed small granulomatous reaction at the insertion sites of the IMP with long protruded cut. Local wound dressing after shortening the cut end allowed good healing.

A dog with semi-tubular plate-pin construct showed protrusion of the screw heads beyond the skin in the medial aspect after primary wound healing (Fig. 4). Radiographs revealed pulling away of one screw in the distal fracture fragment with signs of granulomatous reaction. In spite of that good progression of fracture healing was occurred with ill distinct fracture line and presence of fine bridging callus of even density and smooth borders (Fig. 5).

The dog with wound breakdown, showed development of a sinus tract between exterior and the fracture site. Radiographs revealed signs of osteomyelitis with rough thick proliferative periosteal reaction and cortical bone resorption especially at the fracture edges (Fig. 6).

Two months postoperatively, eight dogs were clinically active with no signs of muscu-

lar atrophy or lameness. Dogs were re-anesthetized and pins were removed through small incision 2 cm at the same site of insertion using bone rongeur (Fig. 7).

Three months postoperatively, clinical examination revealed absence of pain at the fracture site which indicating clinical union. Radiographs revealed progressive healing of the treated tibias manifested by absence of the fracture line without visible callus. Plates were removed through skin incisions over the length of the bone plates. During the removal; the plates found to be covered by normal soft tissue and detached easily from its place. Minimal footprints were perceived beneath the plates (Fig. 8). Wounds were sutured followed by pressure bandage. Restricted movement was recommended for one month.

Radiographs during the period of 4 weeks after removal of plates revealed progressive remodeling of the healed bone. Bones took their normal contour (Fig. 9).

DISCUSSION

The tibial shaft was approached through a crano-medial incision which was along the tibial length originating at the medial tibial condyle and terminating at the medial malleolus. **Denny & Butterworth (2000)** refused to make the incision too medially, as the closure will lie directly over the plate and makes problems with wound healing.

When applying plate-pin construct; the IMP diameter was occupied 35 to 40% of the medullary cavity providing adequate stress protection of the plate while allowing room for the screws to be placed. IMP was inserted by

normograde fashion through a limited cranio-medial approach in the half way between patellar and medial collateral ligaments at the stifle region. The IMPs were slightly curved as they pass down the shaft of the tibia. **Roe (2003); Glyde & Arnett (2006) and Brinker & Daniel (2007)** mentioned that a retrograde insertion of IMPs in tibial fractures probably cause damages of cruciate ligaments, menisci and articular cartilage resulting in pain, lameness and, ultimately, degenerative joint disease which is not the case in this study.

When using plate-pin construct, the IMP resist bending in all directions while overcomes other forces poorly. Auxiliary fixation with bone plates counteract rotational, shearing and torsional forces thus all forces become neutralized at the fracture site during weight-bearing (**Vasseur, 1984; Dallman, et al. 1990; Dueland & Johnson, 1993; Dixon et al., 1994; Dueland et al., 1998 and McLaughlin, 1999**).

Reduction and stabilization of any fracture fragments till application of bone plates was a hard task to be performed and took along time. In plate-pin construct, once the IMP appears at the fracture site and driven into the distal fragment, axial alignment was obtained and final reduction was easy to be made and subsequently easy plate application. These findings coincide with that reported by **Aron et al. (1995); Johnson et al. (1998) and Harason (2002)** who mentioned that soft tissues around the fracture were minimally disrupted thus preserving both fragments vascularity and soft tissue envelope so named by biologic osteosynthesis.

Once the IMP seated; the pin was cut shortly enough so that it was not touch the femoral condyles at full extension of the stifle joint. The same procedure was conducted by **Stone (1981); El-Barrany et al. (1994) and Glyde & Arnett (2006)**. During application of bone plates, cortical screws were angled away from the IMP or the plates were offset slightly to accomplish screws placement as described by **Brinker & Bailey (1997) and Deneuche & Viguler (2002)**.

Although **Johnston et al. (1991) and Egger (1993)** stated that semi-tubular plate used in bones where most of the load is taken by another bone or bones such as metacarpal and radius & ulna in dogs and femur in cat and not sufficient as a sole method for tibial diaphyseal fracture fixation. The present study findings confirm that addition of IMP to the plate reduces the disruptive physiologic loads on the primary implant and virtually eliminates the concentration of stresses at the empty screw holes. Thus semi-tubular plates can be used in treatment of tibial diaphyseal fracture without fear from cyclic bending which can lead to early plate fatigue and screw loosening.

A case of semi-tubular plate-pin construct screw head was protruded beyond the skin and one screw was pulled out. Implant stability was maintained and complete healing was obtained. This could be attributed to the presence of IMP as mentioned by **Singer and Kellam (1995); Chapman and Olson (1996) and Harason (2002)**.

Plate-pin construct compromises a very rigid method of fixation in which healing

occur by primary bone union which not progressed satisfactory unless minor evidence of secondary bone healing is found. Radiographically, a slow filling of the fracture line with bone density material, little or no periosteal callus formation (**Morgan & Leighton, 1995**).

IMPs were removed after radiographic healing resulting in increasing load sharing by the bone, which may further stimulate complete bone healing. This was in agreement with that recorded by **DeYoung & Probst (1993)** and **Olmstead et al. (1995)** who mentioned that pin removal has additional biological benefit of dynamination at the fracture site, as bone is formed where stresses require its presence

and resorbed where stresses do not require it.

In the present study, during removal of bone plates in plate-pin constructs, faint footprints were perceived beneath the plate in all treated cases and no cases of re-fracture was recorded. This could be explained as the internal fixator design of plate-pin construct has the advantage that number of screws are much less, the screws were mostly monocortical and subsequently screw insertion does not draw the bony fragments to the plate and hence, the precise contouring of the plate is less important in achieving accurate fracture reduction and preserving periosteal blood supply (**Uhthoff et al., 1994; Cordey et al., 2000; Frigg, 2001 and Perren, 2002**).

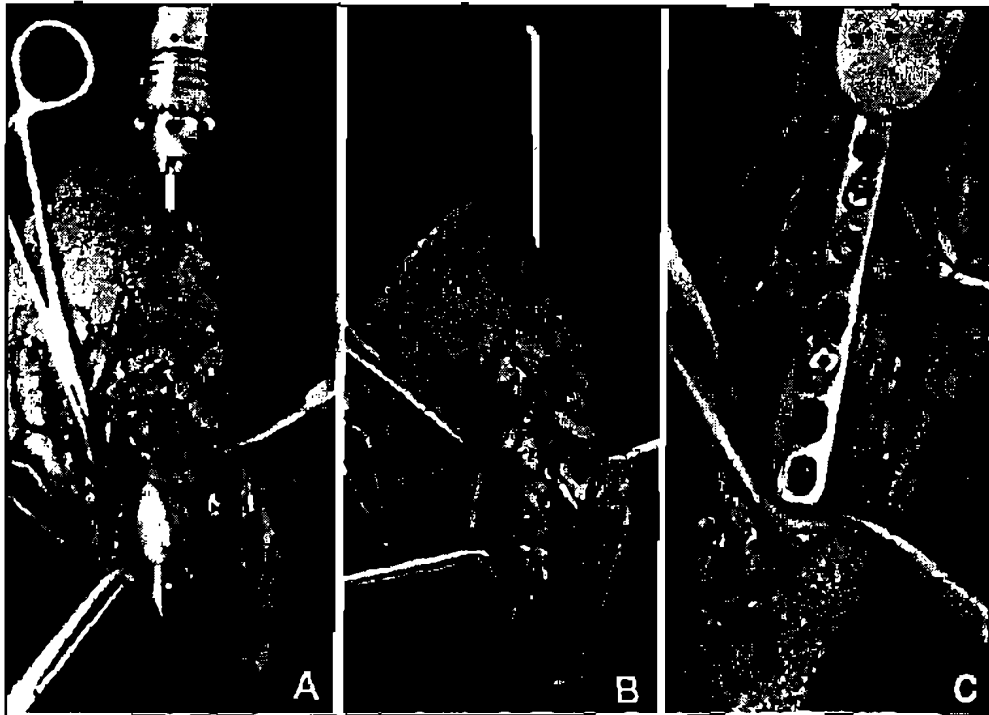


Fig. (1) Showing:

Plate pin construct application: IMP was inserted by normograde fashion till emerging from the distal end of the proximal fragment (A) axial alignment was obtained just after the pin was driven into the distal fragment (B) partial stability was obtained allow easy application of DCP (C).

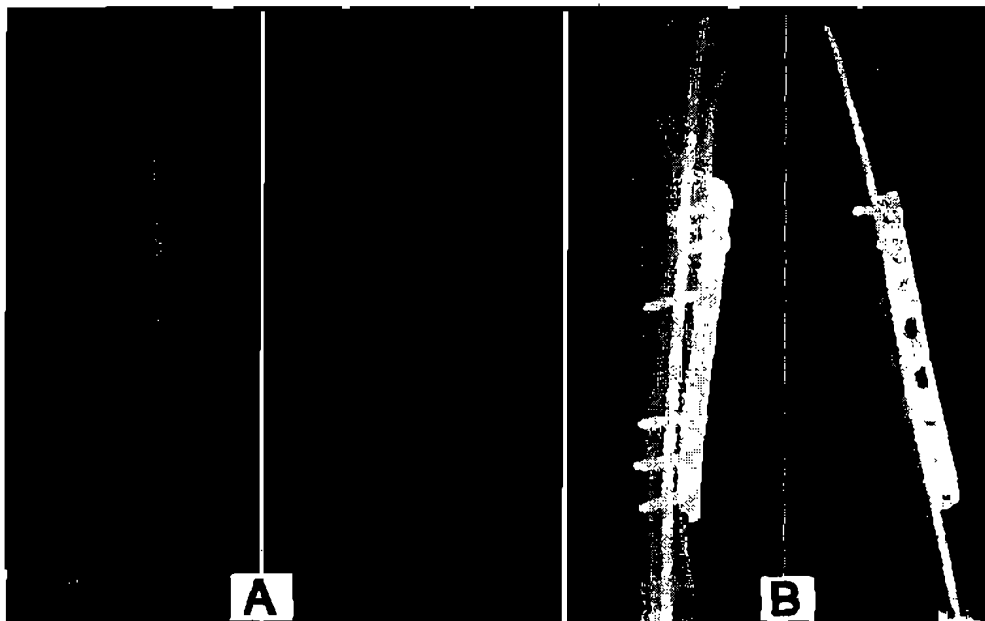


Fig. (2): Preoperative (A) and postoperative (B) antero-posterior and medial radiographs showing application of DC plate-pin construct with proper fracture reduction. Note: application of two monocortical screws and four bicortical screws.

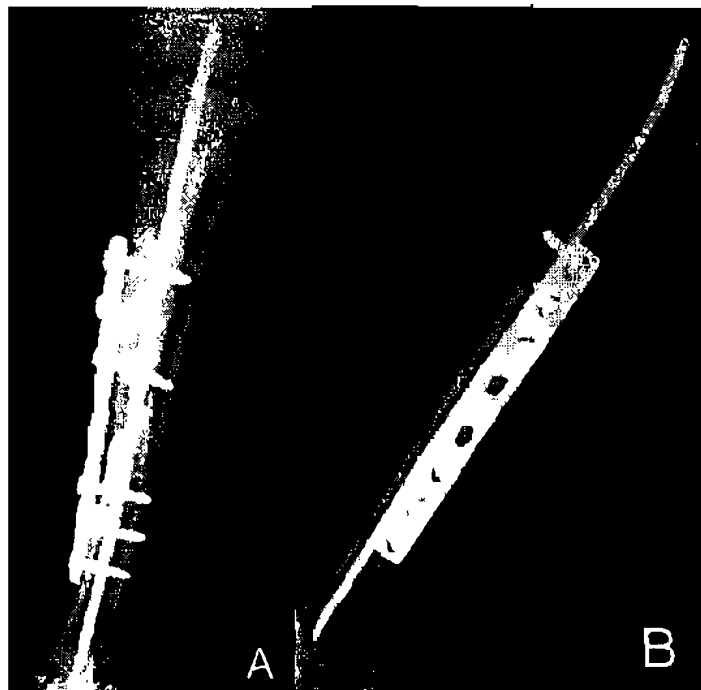


Fig. (3): Antero-posterior (A) and Medial (B) radiographs of DC plate-pin construct at one month postoperatively showing ill distinct fracture line. Note: no visible bridging callus.



Fig. (4) Showing :
Protrusion of five screw heads (arrows) of the semi-tubular plate beyond the skin in the medial aspect of the tibia after primary wound healing.

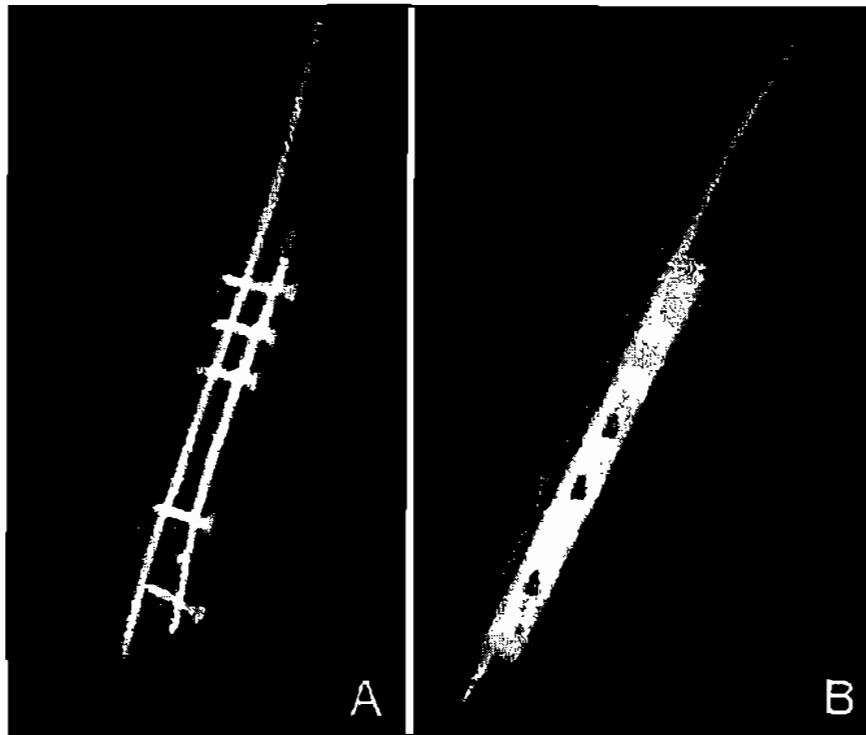


Fig. (5): Antero-posterior (A) and Medial (B) radiographs of semi-tubular plate-pin construct at one month postoperatively, showing pulling away of one screw (arrow) in the distal fracture fragment. Note: complete disappearance of the fracture line and presence of fine bridging callus of even density and smooth borders.

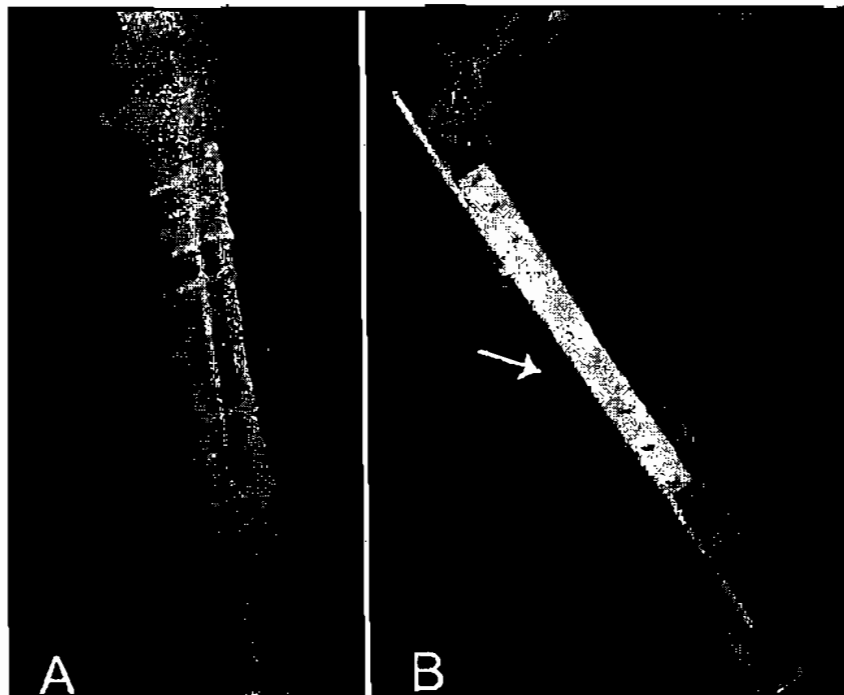


Fig. (6): Antero-posterior (A) and Medial (B) radiographs of Dc plate-pin construct showing active signs of osteomyelitis with rough thick proliferative periosteal reaction and cortical bone resorption especially at the fracture edges (arrow).



Fig. (7) Showing:
Antero-posterior and Medial radiographs two months postoperatively; of DC plate-pin construct; before (A) and after (B) removal of the steinmann IMP.

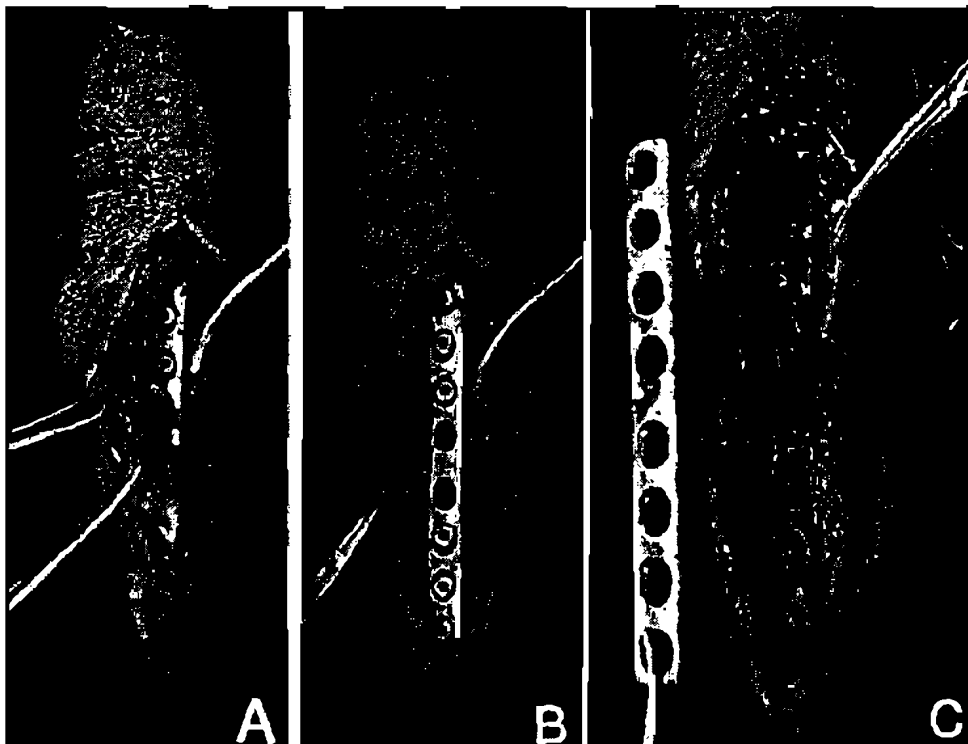


Fig. (8) : Showing removal of DC plate-pin construct three months postoperatively; normal soft tissue covered the plate (A) the plate was detached easily (B) minimal footprint was perceived beneath the plate (C).

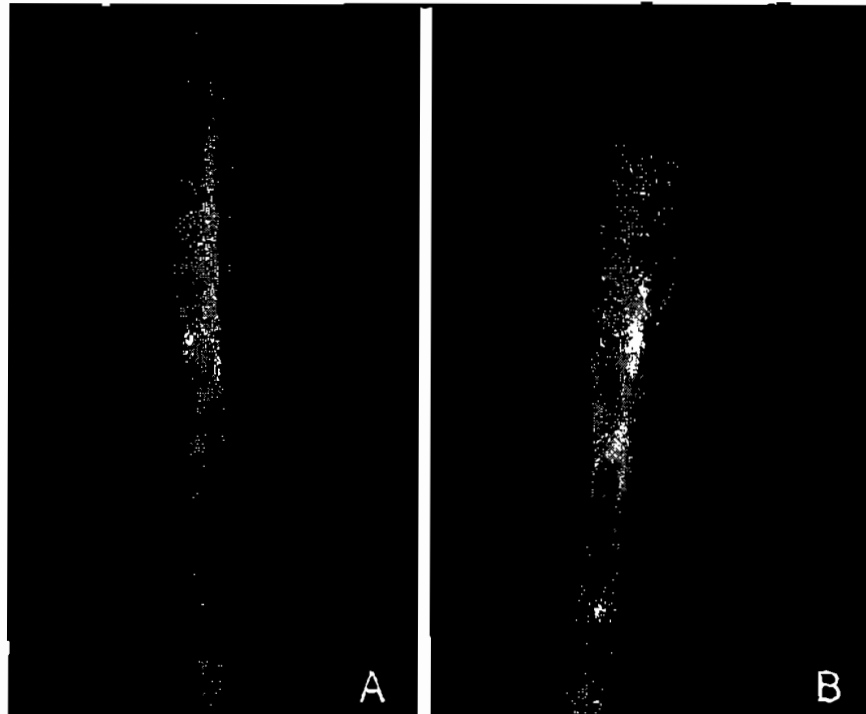


Fig. (9): Antero-posterior (A) and Medial (B) radiographs of repaired tibial diaphysis 4 weeks after removal of the DCP showing progressive remodeling of the healed bone, no callus formation and normal bone remodeling.

REFERENCES

- Aron, D. N.; Palmer, R. H. and Johnson, A. L. (1995)** : Biologic strategies and a balanced concept for repair of highly comminuted long bone fractures, *Compend Cont Educ Pract Vet*; 17: 35-49.
- Braden, T. D.; Eicker S. W.; Abdinoor O. and Prieur W. D. (1995)** : Characteristics of 1000 femur fracture in dog and cat. *J. Vet. Comparat. Orthop. Traumatol.*; 8 : 203-209.
- Brinker, M. R. and Bailey, D. E. (1997)** : Fracture healing in tibia, fractures with an associated vascular injury. *J Trauma*; 42(1):11-19.
- Brinker, M. R. and Dantel, P. O. (2007)** : Exchange Nailing of Ununited Fractures. *J Bone Joint Surg Am.* 89:177-188.
- Caudel, R. J. and Stern, P. J. (1987)** : Severe open fractures of the tibia. *J Bone Joint Surg*; 69: 801-807.
- Chapman, M. W. and Olson, S. A. (1996)** : Open fractures in Rockwood C.A. and Green R.W. Editors: *Fractures in adults*, 4th ed. Philadelphia: Lippincott-Raven.
- Cordey, J.; Perren, S. M. and Steinmann, S. G. (2000)** : Stress protection due to plates: Myth or reality? A parametric analysis made using the composite beam theory. *Injury, Int J Care Injured*, 31: 1-13.
- Dallman M. J.; Martin R. A.; Self B. P. and Grant J. W. (1990)** : Rotational strength of double pinning technique in repair of transverse fractures in femur of dogs. *Am. J. Vet. Res*; 51(1): 115-118.
- Deneuche, A. J. and Viguer, E. (2002)**: reduction and stabilization of a supraglenoid tuberosity avulsion under arthroscopic guidance in a dog. *J small Anim Prac*; 43(7): 308-311.
- Denny, H. R. and Butterworth, S. J. (2000)**: The Tibia and Fibula. Chapter 43. *A Guide to Canine and Feline Orthopedic Surgery*, 554-574.
- DeYoung, D. J. and Probst, C. W. (1993)**: Methods of internal fracture fixation - general principles. In Slatter, D.(ed): *Textbook of small animal surgery*. W.B Saunders Co., Philadelphia, 1610-1631.
- Dixon, B. C.; Tomlinson, J. L. and Wagner-Mann, C. C. (1994)** : Effects of three intramedullary pinning techniques on proximal pin location and articular damage in the canine tibia. *Vet Surg*; 23: 448-455.
- Dueland R. T. and Johnson K. A. (1993)** : Interlocking nail fixation of diaphyseal fractures in the dog. A multi-center study of 1991-1992 cases. *J Vet. Surg*; 22: 377-381.
- Dueland, R. T.; Berglund L. and Vanderby, R. Jr. (1996)**: Structural properties of interlocking nails, canine femora, femur-interlocking nail contrasts. *J Vet Surg*; 25: 386-396.
- Egger, E. L. (1993)** : Fractures of the radius and ulna. In Slatter D.H. ed. *Textbook of small animal surgery*. W.B. Saunders Co. Philadelphia.
- Ei-Barrany, W. G. and Abd El.Megid, A. A. (1994)** : blood supply of the tibia and its importance in tibial bone grafts. *Egypt. J. Anat.*, 17(4): 451- 470.
- Frigg, R. (2001)** : Locking compression plate (LCP). An osteosynthesis plate based on the dynamic compression plate and point contact fixator (PC-Fix). *Injury*; 32: 63-6.
- Gautrux, E.; Perren, S. M. And Gauze, R. (1992)** : Principles of internal fixation. *Curr. Orthop*; 6: 220-230.
- Glyde, M. and Arnett, R. (2006)** : Tibial fractures in the dog and cat: options for

management. *Irish Veterinary Journal*; 59(5): 290-95.

Gorse, M. J. (1998) : Using external skeletal fixation for fractures of the radius and ulna and tibia. *Vet. Med*; 93: 463-467.

Harason, G. (2002) : Biologic repair of fractures. *Can. Vet. J*; 43: 299-301

Harason, G. (2003) : Common long bone fracture in small animal practice-part 2. *Can Vet J*; 44(6): 503-4.

Hickman, J.; Houlton, J. F. F. and Edward, B. (1995) : An Atlas of Vet. Surg. 3rd ed. Blackwell Science.

Hulse, D. A. and Johnson, A. L. (1997) : Management of specific fractures. In Fossum TW (ed): *Small Animal Surgery*; 767-882.

Im G. I. and Tae S. K. (2005) : Distal metaphyseal fractures of tibia: a prospective randomized trial of closed reduction and intramedullary nail versus open reduction and plate and screws fixation. *J Trauma*; 59(5): 1219-23.

Johnson, A. L.; Smith, C. W. and Schaeffer, D. J. (1998) : Fragment reconstruction and bone plate fixation versus bridging plate fixation for treating highly comminuted femoral fractures in dogs: 35 cases (1987-1997). *J AmVet Med Assoc*; 213: 1157-1161.

Johnson, J. A.; Austin, C. and Breur, G. J. (1994): Incidences of canine appendicular musculoskeletal disorders in 16 veterinary teaching hospitals from 1980 through 1989. *Vet. Comp. Orthop. Trauma* 7: 56-69.

Johnston, S. A.; Lancaster, R. L.; Hubbard, R. P. and Probst, C. W. (1991) : A biomechanical comparison of 7-hole 3.5 mm broad and 5-hole 4.5 mm narrow dynamic compression plates. *Vet Surg*; 20(4): 235-239.

McLaughlin, R. (1999) : Internal fixation. Intramedullary pins, cerclage wires and inter-

locking nails. *Vet. Clin. North Am. Small Anim. Pract*; 5: 1097-1116.

Morgan, J. P. and Leighton, R. L. (1995): Radiographic appearance of fracture healing. In *Radiology of Small Animal Fracture Management*. W.B Saunders co., Philadelphia, pp 34-42.

Olmstead, M. L.; Egger, E. L. and Johnson, A. L. (1995) : Principles of fracture repair In Olmsted M.L.(ed): *Small animal orthopedist* St. Louis, Mosby, pp 11-159.

Palmer, R. H. (1999) : Biological osteosynthesis. *Vet Clin North Am Small Anim Pract*; 29: 1171-1185.

Perren, S. M. (1991) : The concept of biological plating using the limited contact-dynamic compression plate (LC-DCP). *Scientific background, design and application Injury*; 22(1): 1-41.

Perren, S. M. (2002) : Evolution of the internal fixation of long bone fractures. The scientific basis of biological internal fixation: choosing a new balance between stability and biology. *J Bone Joint Surg*; 84: 1093-110.

Piermattel, D. L. (1993) : An atlas of surgical approaches to the bones and joints of the dog and cat. (3rd ed). Philadelphia, PA, Saunders.

Roe, S. C. (2003) : Internal fracture fixation, In Slatter D (ed): *Textbook of Small Animal Surgery*. Philadelphia, PA, Saunders. 2 (ed 3): 1798-1818.

Singer, R. W. and Kellam, J. F. (1995) : Open tibial diaphyseal fractures: Results of unreamed locked intramedullary nailing. *Clin Orthop*; 9: 77-120.

Stiffler, K. S. (2004) : Internal fracture fixation. *Clin. Tech. Small. Anim. Pract.*; 19(3): 105-13.

Stone, E. A. (1981) : Effect of Rush pins

on the distal femoral growth plate of the young dog. *Am. J. Vet. Res.*; 42: 261.

Tornetta P.; Bergman, M. and Watnik, D. (1994) : Treatment of grade IIIB open tibia fractures: a prospective randomized comparison of external fixation and non-reamed locked nailing. *J Bone Joint Surg*; 76: 13-19.

Uhthoff, H. K.; Bolsvert, D. and Finne-

gan, M. (1994) : Cortical porosis under plates. Reaction to unloading or to necrosis. *Am. J. Bone. Joint. Surg.*; 76(10): 1507-1512

Vasseur P. B. (1984) : Evaluation of fixation devices for prevention of rotation in transverse fractures of the canine femoral shaft. An in vitro study. *Am. J. Vet. Res.*; 45: 1504-9.

الملخص العربى

تقييم إستخدام مسمار النخاع مع شرائح العظام لرأب الكسور فى منتصف عظمة القصبة فى الكلاب

آلاء سامى د / عصام مصباح
أ. د / جمال قروف أ. د / عادل التابعى زغلول
نسم الجراحة والتخدير والأشعة - كلية الطب البيطرى - جامعة المنصورة

تشكل جراحة العظام وعلاج الكسور مشكلة رئيسية فى جراحة الحيوانات لاسيما فى الكلاب، وقد وقع الاختيار على عظمة القصبة بسبب ارتفاع نسبة الكسور بها والتي يمكن أن تحدث على أى مستوى، علاوة على أنها تعتبر من الإصابات الخطيرة التي تستغرق وقتاً طويلاً للإلتئام.

أجريت هذه الدراسة التجريبية على عدد 10 من الكلاب اليانعة السليمة صحياً حيث بزن كل منهم حوالى 20 كجم، وتم إحداث كسور فى منتصف عظمة القصبة لهذه الحيوانات حيث أجرى لها العلاج بالرد والتثبيت الداخلى بواسطة مسمار النخاع (Steinmann pin) مع شرائح العظام سرا - كانت شرائح ذات الضغط الديناميكي (DCP) والشرائح النصف أنبوبية (semi-tubular plate) بحيث كان قطر مسمار النخاع 35-40% من تجويف النخاع لعظمة القصبة، وقد تم تثبيت هذه الشرائح باستخدام مسامير أحادية القشرة وأخرى ثنائية القشرة.

تم متابعة هذه الكسور سريريا وباستخدام الأشعة السينية منذ إحداثها وخلال فترة إلتئامها وبعد إزالة مسمار النخاع ثم إزالة الشرائح للوقوف على مراحل الإلتئام.

وقد أثبتت النتائج نجاح إستخدام مسمار النخاع مع شرائح العظام وخصوصاً الشرائح ذات الضغط الديناميكي كطريقة ملائمة ومثلى فى علاج كسور عظمة القصبة فى الكلاب.