

A study on the Effect of Erythropoietin Treatment on Healing of Renal Damage in Male Albino Rats

Romysa A. El-Sherbeny and Mohamed N. Abd El-Rahman
Physiology and Pharmacology Departments,
Faculty of Medicine, Tanta University

ABSTRACT

This study investigated the healing effect of erythropoietin treatment on renal damage in male albino rats. This work was carried out on 24 male albino rats, divided into four equal groups. Group (1) Control group: injected by 0.2ml saline intraperitoneally (2) Mercuric chloride (HgCl₂) treated group: rats were injected intraperitoneally by single dose (3mg/kg) of HgCl₂, group(3): Erythropoietin (Epo) treated group: rats were treated by intraperitoneal injection of Epo (1000u/kg) /day for 2 weeks, and group (4) HgCl₂ and Epo treated group: rats were injected by single dose of HgCl₂ and Epo for 2 weeks. At the end of experimental period, rats were sacrificed and blood samples were collected and sera were separated for estimation of serum levels of creatinine, urea, glutathione peroxidase, glutathione concentration, malondialdehyde and haematocrit value. The abdomen was dissected and kidney was excised and fixed in formalin for histopathological examination. The results showed in HgCl₂ treated group, significant increase in serum creatinine, urea and malondialdehyde levels, and significant reduction in glutathione concentration, glutathione peroxidase and haematocrit value (HV) levels compared with control. Epo treated group showed significant reduction in serum levels of creatinine, and malondialdehyde, and significant increase in HV value levels, compared with the control. HgCl₂ and Epo treated group showed, significant reduction in malondialdehyde, creatinine and urea and significant increase in glutathione concentration, glutathione peroxidase and HV compared with HgCl₂ group. Histopathological examination showed necrosis of renal tubular epithelium and dilated proximal and distal tubules and wide Bowman's capsule in HgCl₂ treated group. HgCl₂ and Epo treated group showed improvement of renal tubular epithelium, mild dilatation of Bowman's capsule and bone marrow derived cells. It is concluded that, Epo treatment improved renal damage due to HgCl₂ and promote healing of renal tissue, and it is recommended to be used in chronic renal disease.

INTRODUCTION

Erythropoietin is present in human milk⁽¹⁾. During fetal life, enterocytes are exposed to erythropoietin (Epo) contained in swallowed amniotic fluid⁽²⁾, and in

breast fed infants exposed to internal Epo in mothers milk⁽³⁾.

Recovery of renal function after tubular damage, whether ischemic or toxic depends on the replacement of lost epithelial cells. The new epithelial cells may originate from endogenous renal cells, or from cells derived from

bone marrow⁽⁴⁾. Adult stem cell plasticity, is a phrase that has been used to describe a change in cell fate, such as, from bone marrow to renal tissue, but it should be made clear that, there is no well-defined renal stem cell population within the adult mammalian kidney⁽⁵⁾. Bone marrow allograft contributions to renal tubular parenchyma in human and mice⁽⁶⁾, that contained Y chromosome-positive cells developed epithelial cells in acute tubular necrosis⁽⁷⁾. Several studies have defined the observation that, bone marrow gives rise to renal parenchyma⁽⁴⁾. An example of a haematopoietic stem cells population from male mice, helped in the regeneration of renal tubular epithelium after renal ischemic injury⁽⁸⁾, and transient ischemia mobilized stem cells population into the circulation from bone marrow, forming bone marrow-derived renal tubular epithelial cells⁽⁹⁾. Several groups have to identify factors that accelerate recovery from renal injury, and some have tested HgCl₂ whether it affect bone marrow to kidney cell trafficking⁽¹⁰⁾, or it may be due to changes in cytokine⁽¹¹⁾. Considering the cytokine which might be involved is Epo, which has emerged as a most promising multifunctional cytokine that can play a significant role in regeneration of the kidney⁽¹²⁾. Epo is produced mainly by peritubular fibroblast within the adult kidney in response to hypoxia. The released Epo into circulation primarily is the main factor for regulation of red cell population in bone marrow, by preventing apoptosis of erythroid progenitor cells. Epo receptors have been localized in several

haematopoietic tissues, brain, retina, heart, lung, spleen, kidney and endothelial cells⁽¹³⁾.

Mercuric chloride (HgCl₂) is a toxin that causes renal damage, as it affects the S₃ segment of the proximal tubules selectively⁽¹⁴⁾, causing direct acute tubular necrosis, which doesn't suppress division of endogenous renal cells. The aim of the present work was to study the effect of erythropoietin in renal damage induced by mercuric chloride (HgCl₂) in male albino rats.

MATERIAL & METHODS

This study was carried out on 24 male albino rats aged 8 weeks and weighing 140-180 gm. The rats were kept individually in cages and fed milk and bread and had free water access. The rats were divided into four group each containing 6 rats.

Group (1): Control group: rats were injected intraperitoneally by 0.2 ml saline daily for two weeks.

Group (2): Mercuric chloride treated group: rats were injected by a single dose of HgCl₂ (Sigma) in a dose of 3mg/kg BW⁽¹⁴⁾ intraperitoneally.

Group (3): Erythropoietin treated group: rats were injected Epo (Amoun) intraperitoneally in a dose of 1000 u/kg BW/ day⁽¹⁵⁾ for two weeks.

Group (4): Erythropoietin and HgCl₂ treated group: rats were treated by single dose of HgCl₂, and Epo by intraperitoneal injection in a dose of 1000u/kg BW/day for two weeks.

At the end of experiment, no treatment was given for three days, then the rats were scarified, and blood samples were collected, and sera were separated for determination of the following parameters:

Serum creatinine according to the method of Henry⁽¹⁶⁾.

Serum urea according to the method of Patton and Crouch⁽¹⁷⁾.

Glutathione concentration by fluorometric method of Hissin and Hi fi⁽¹⁸⁾.

Glutathione peroxidase by the method of Splittgerber and Tappel⁽¹⁹⁾.

Serum malondialdehyde by the method of Buege and Aust⁽²⁰⁾.

Haematocrit value% is measured by the method of Henry⁽¹⁶⁾.

The abdominal cavity was opened, kidney was excised and fixed in 10% formalin for histopathological examination.

Statistical analysis

The results were expressed as means \pm SD. A two way analysis of variance was used to analyze data, that were considered significant when P values were less than 0.05.

RESULTS

The results of the present work are shown in table (1):

Serum creatinine level (mg/dl):

Results showed, significant increase of serum creatinine in HgCl₂ treated group compared with the control group, P< 0.05. The Epo treated group showed, significant decrease of serum creatinine compared with the control group, P< 0.05. The HgCl₂ and EPO treated group showed significant increase of serum creatinine compared with the control group, and significant reduction compared with HgCl₂ treated group, p< 0.05, Fig (1).

Serum urea level (mg/dl):

Results showed, significant increase of serum urea in HgCl₂

treated group compared with the control group, P<0.05. The Epo treated group showed, non significant reduction of serum urea compared with the control group. The HgCl₂ and EPO treated group showed significant increase of serum urea compared with the control group, and significant reduction compared with the HgCl₂ treated group, P< 0.05, Fig (2).

Glutathione concentration(umol/L):

Results showed significant reduction of glutathione level in HgCl₂ treated group compared with the control group, P< 0.05. Epo treated group showed, non significant increase of glutathione compared with the control group. HgCl₂ and Epo treated group showed significant reduction of glutathione concentration compared with the control group, and significant increase compared with the HgCl₂ treated group, P< 0.05, Fig (3).

Glutathione peroxidase level (u/gmHb):

Results showed significant reduction of glutathione peroxidase in HgCl₂ treated group compared with the control group, P<0.05. Epo treated group showed insignificant increase compared with the control. Epo and HgCl₂ treated group showed, significant reduction of glutathione peroxidase level compared with the control group, and significant increase compared with HgCl₂ treated group, P< 0.05, Fig (4).

Malondialdehyde level (umol/ml):

Results showed significant increase of malondialdehyde level in HgCl₂ treated group compared with the control group, P<0.05. Epo treated group showed significant reduction in malondialdehyde compared with the control group, P< 0.05. HgCl₂ and

Epo treated group showed significant increase of serum malondialdehyde level compared with the control group, and significant reduction of malondialdehyde level compared with HgCl₂ treated group, P<0.05, Fig(5).

Haematocrit value %:

The results showed significant reduction of HV% in HgCl₂ treated group compared with the control group, P<0.05. Significant increase of HV% in group treated by Epo compared with the control group, P<0.05. The HgCl₂ and Epo treated group showed significant increase of HV% compared with the control and

significant increase compared with the HgCl₂ treated group, P<0.05, Fig(6).

Histopathological examination showed:

Kidney of control group, with normal Bowman's capsule, normal convoluted tubules and collecting duct Fig (7). Kidney treated by HgCl₂, showed extensive necrosis of tubular epithelial cells, dilatation of proximal and distal renal tubules and wide Bowman's capsule Fig (8). Kidney treated by HgCl₂ and Epo showed improvement of renal tubules and mild dilatation of Bowman's capsule, mild congestion of renal stroma and bone marrow derived cells Fig (9).

Table (1): Effects of erythropoietin and HgCl₂ treatment on serum creatinine, urea, glutathione concentration, glutathione peroxidase activity, malondialdehyde and haematocrit value (mean $\bar{x} \pm$ SD).

Parameter	Control	HgCl ₂	Epo	Epo and HgCl ₂
Serum creatinine mg/dL	0.9±0.05	2.88±0.04*	0.71±0.05*	1.08±0.15*
Serum urea mg/dL	24.86±0.43	79±9.6*	23.83±0.23	65.5±7.8*
Glutathione concentration umol/L	11.86±0.43	6.74±0.92*	12.25±0.39	9.63±0.58*
Glutathione peroxidase u/gm Hb	22.28±1.64	16.53±0.53*	23.55±0.72	18.92±1.44*
Malondialdehyde umol/mL	1.5±0.09	2.48±0.24*	1.30±0.1*	1.75*±0.1
Haematocrit value %	38.06±0.95	35.35±1.48*	44.6±1.46*	40.7±1.49*

*= Denotes statistical significance

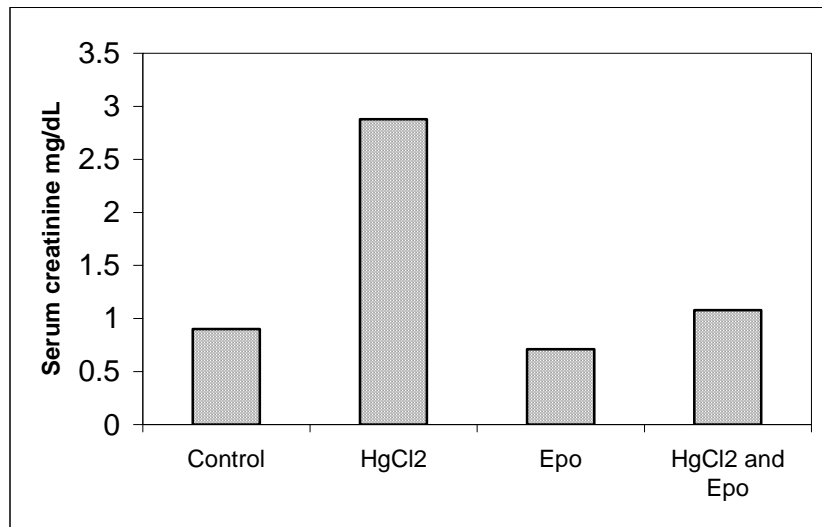


Fig (1): Effect of Epo and HgCl₂ treatment on serum creatinine level mg/dL in male albino rats

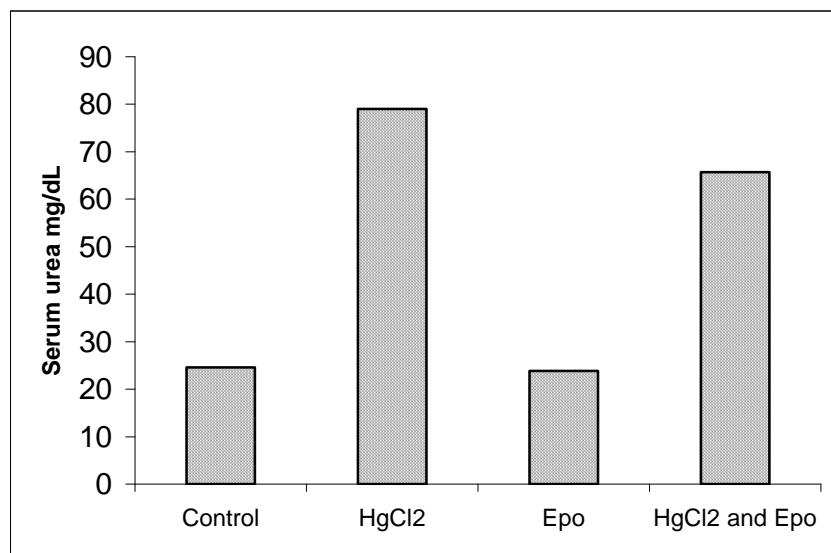


Fig (2): Effect of Epo and HgCl₂ treatment on serum urea mg/dL level in male albino rats

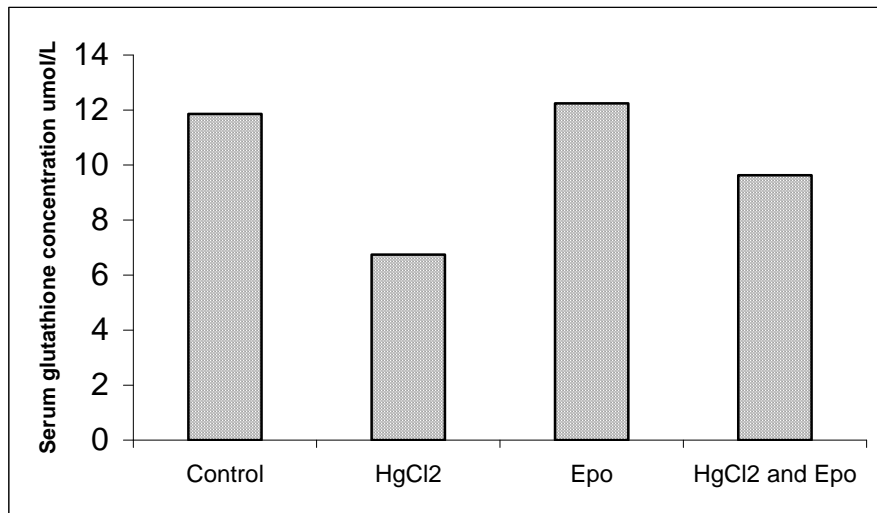


Fig (3): Effect of Epo and HgCl₂ treatment on serum glutathione concentration umol/L in male albino rats

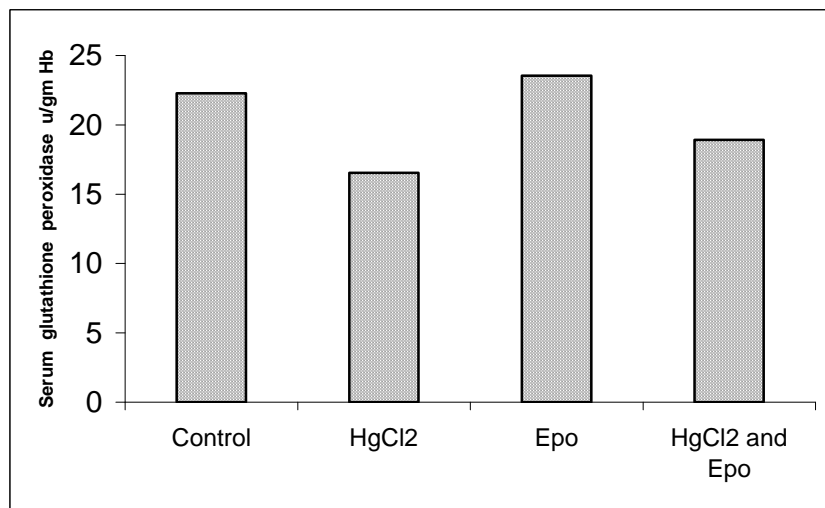


Fig (4): Effect of Epo and HgCl₂ treatment on serum glutathione peroxidase u/gm Hb in male albino rats

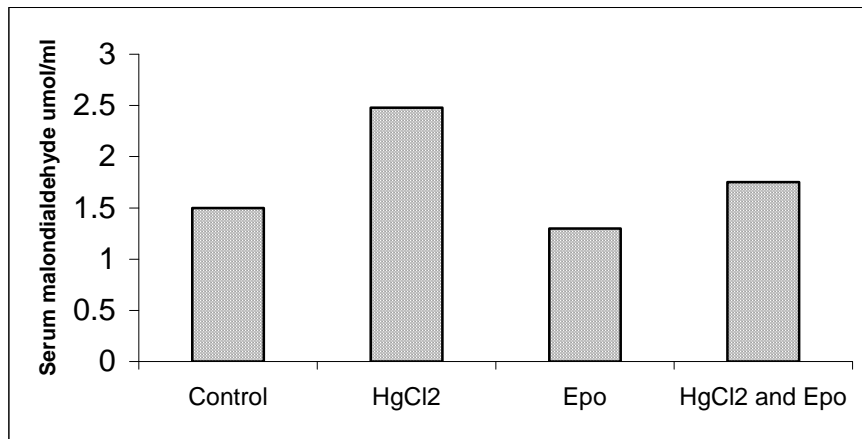


Fig (5): Effect of Epo and HgCl2 treatment on serum malondialdehyde umol/mL in male albino rats

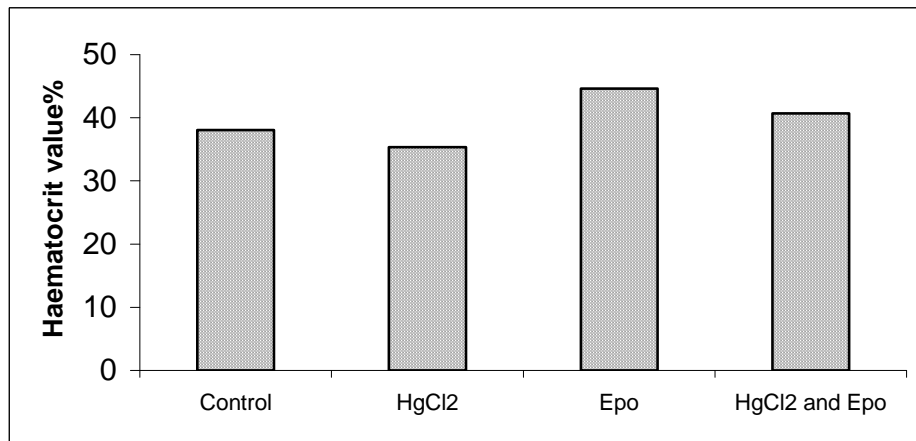


Fig (6): Effect of Epo and HgCl2 treatment on Haematocrit value % in male albino rats

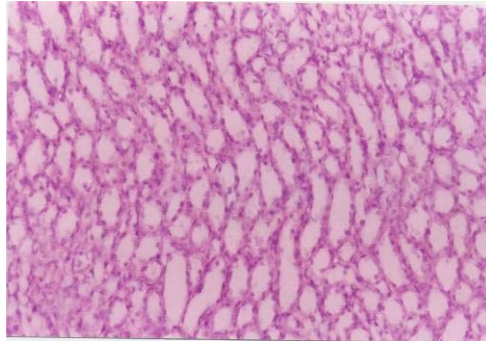


Fig (7): Section in rat kidney of control group showing normal Bowman's capsules, normal convoluted tubules and collecting ducts (H&E Mag x125)

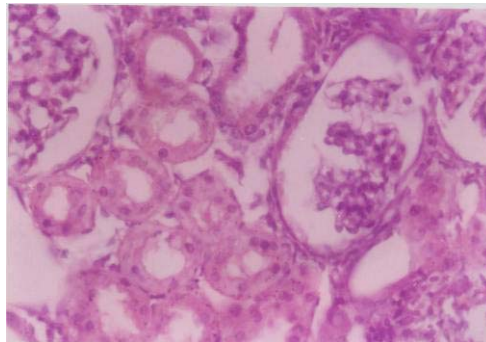


Fig (8): Section of rat kidney damaged by HgCl₂ showing widening of Bowman's capsules, severe degeneration of convoluted tubules (H&E Mag x250).

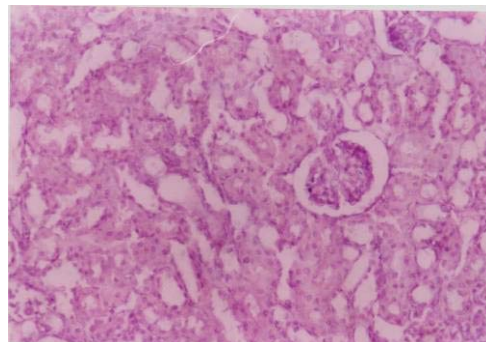


Fig (9): Section of rat kidney treated by HgCl₂ and Epo showing marked improvement of convoluted tubules, mild congestion, bone marrow derived cells (H&E Mag x250).

DISCUSSION

The adult mammalian kidney has no well-defined stem cell population, and is unable to produce new nephrons in responses to metabolic demand or damage⁽²²⁾. Tubular cell turnover and regeneration were thought by most to occur by expansion of the resident epithelium⁽²³⁾. The results of the present work showed that, the HgCl₂ treated group showed impairment of renal function and degeneration of renal tubules in the form of acute tubular necrosis. Erythropoietin treatment increased haematocrit levels, which confirms Epo main biological activity, and improvement of renal function that was disturbed by HgCl₂ and caused reduction of serum creatinine and urea. Also the improvement of healing of renal tubules and reduction of fat oxidation product malondialdehyde and elevation of glutathione concentration and glutathione peroxidase. Glutathione serves as a major protective substrate against many foreign toxic substances, and clears oxidative intermediates that are formed in the cell. Because of its involvement in the metabolism of oxygen free radicals and toxic metabolites, depletion of glutathione peroxidase has been used as an index of oxidative stress⁽²⁴⁾. It protects cells and prevents the oxidative damage by fat oxidation products, unsaturated fatty acids which increased in renal damage, and caused reduction of glutathione peroxidase and increase in lipid oxidation products, malondialdehyde⁽²⁵⁾.

The role of Epo in improvement and healing of renal tubules may be explained by the anti-apoptotic action of erythropoietin on various tissues of body including heart⁽¹³⁾, and kidney⁽²⁶⁾. Also, the mechanism of renal protection and healing after heavy metal toxicity may be due to stimulation of bone marrow and increasing the number of bone-marrow-derived tubular cells⁽²⁷⁾. The histopathological examination showed improvement of renal damage in HgCl₂ and Epo treated group, which showed as regeneration of renal tubules and appearance of bone marrow derived cells, with the improvement of renal function, as reduction of serum creatinine and urea. These results may be due to some circulating factors that might be involved, especially erythropoietin which emerged as a most promising multifunctional cytokine that can play a significant role in regeneration of the kidney^(15,28). In the circulation, the primary recognized role of Epo, is the regulation of red cell production in the bone marrow (by preventing apoptosis of erythroid progenitor cells)⁽²⁹⁾. Several groups have thought to identify factors that accelerate recovery from renal injury and some have tested whether they affect bone marrow-to-kidney cell trafficking. Iwasaki et al.⁽¹⁰⁾, reported that, cisplatin-induced renal failure, showed bone marrow-derived cells mobilized by granulocyte-colony-stimulating factor (G-CSF) that accelerated the recovery of renal function and prevented renal tubular injury. Regeneration after renal damage by Epo treatments is assisted

by recovery from acute tubular necrosis, which proved as improved renal functions and the prevalence of regenerative bone marrow derived tubular epithelial cells⁽¹¹⁾. In addition, it may be suggested that erythropoietin has Epo receptor gene on tissues, that may respond by activation or inhibition of growth⁽³⁰⁾. Moreover Epo healing effect may be due to stimulation of leptin, that induces autocrine and paracrine cascades and promotes proliferation of epithelial cells⁽³¹⁾. Also, renal healing may be explained by the transgenic action of erythropoietin, which is performed through growth hormone action on protein, Epo passed to blood stream and fused with growth hormone for transfer of protein to the healing epithelium⁽³²⁾. Moreover, Epo has a trophic effect on rat stomach and induced growth and proliferation of gastric mucosal cells⁽³³⁾.

Conclusion and Recommendation:

It is concluded that erythropoietin treatment in renal damage promotes healing of renal tissue. It is recommended that patient with chronic renal disease to treated by Epo.

Acknowledgment

Great thanks for Karema Eldesoky Professor of Pathology for her help in the pathological part of the work.

REFERENCES

1. **Juul SE, Zhao Y, Dame JB, Du Y, Hutson AD, Christensen RD (2000):** Origin and fate of erythropoietin in human milk. *Pediatr Res.*; 48(5):660-7
2. **Richey SD, Ramin SM, Bawdon RE, Roberts SW, Dax J, Roberts J, Gilstrap LC (1995):** Markers of acute and chronic asphyxia in infants with meconium-stained amniotic fluid. *Am J Obstet Gynecol.*;172(4 Pt 1):1212-5.
3. **Carmichael RD, LoBue J, Gordon AS (1992):** Neonatal erythropoiesis. II. Bone marrow and splenic erythropoietic activity: data suggest erythropoietin transfer via maternal milk. *Endocr Regul.*; 26(3):143-9.
4. **Poulsom R, Forbes SJ, Hodivala-Dilke K, Ryan E, Wyles S, Navaratnasah S, Jeffery R, Hunt T, Alison M, Cook T, Pusey C, Wright NA (2001):** Bone marrow contributes to renal parenchymal turnover and regeneration. *J. Pathol*; 195: 229–235.
5. **Alison MR, Poulsom R, Jeffery R, Dhillon AP, Quaglia A, Jacob J, Novelli M, Prentice G, Williamson J, Wright NA (2000):** Hepatocytes from non-hepatic adult stem cells. *Nature*; 406: 257.
6. **Gupta S, Verfaillie C, Chmielewski D, Kim Y, Rosenberg ME (2002):** A role for extra renal cells in the regeneration following acute renal failure. *Kidney Int*; 62: 1285–1290.
7. **Mengel M, Jonigk D, Marwedel M, Kleeberger W, Bredt M, Bock O, Lehmann U, Gwinner W, Haller H, Kreipe H (2004):** Tubular chimerism occurs regularly in renal allografts and is

- not correlated to outcome. *J. Am. Soc. Nephrol*; 15: 978–986.
8. **Lin F, Cordes K, Li L, Hood L, Couser WG, Shankland SJ, Igarashi P (2003):** Hematopoietic stem cells contribute to the regeneration of renal tubules after renal ischemia-reperfusion injury in mice. *J. Am. Soc. Nephrol*; 14: 1188–1199.
 9. **Kale S, Karihaloo A, Clark PR, Kashgarian M, Krause DS, Cantley LG (2003):** Bone marrow stem cells contribute to repair of the ischemically injured renal tubule. *J. Clin. Invest*; 112:42–49.
 10. **Iwasaki M, Adachi Y, Minamino K, Suzuki Y, Zhang Y, Okigaki M, Nakano K, Koike Y, Wang J, Mukaide H, Taketani S, Mori Y, Takahashi H, Iwasaka T, Ikehara S (2005):** Mobilization of bone marrow cells by G-CSF rescues mice from cisplatin-induced renal failure, and M-CSF enhances the effects of G-CSF. *J. Am. Soc. Nephrol*; 16: 658–666.
 11. **Togel F, Isaac J, Westenfelder C (2004):** Hematopoietic stem cell mobilization-associated granulocytosis severely worsens acute renal failure. *J. Am. Soc. Nephrol*; 15: 1261–1267.
 12. **Sharples EJ, Patel N, Brown P, Stewart K, Mota-Philipe H, Sheaff M, Kieswich J, Allen D, Harwood S, Raftery M, Thiemermann C, Yaqoob MM (2004):** Erythropoietin protects the kidney against the injury and dysfunction caused by ischemia-reperfusion. *J. Am. Soc. Nephrol*; 15: 2115–2124.
 13. **Olsen NV (2003):** Central nervous system frontiers for the use of erythropoietin. *Clin. Infect. Dis*; 37 (Suppl. 4):S323–S330.
 14. **Hultman P, Enestrom S (1986):** Localization of mercury in the kidney during experimental acute tubular necrosis studied by the cytochemical Silver Amplification method. *Br. J. Exp. Pathol* 67: 493–503.
 15. **Kang DH, Park EY, Yu ES, Lee YS, Yoon KI (2005):** Reno protective effect of erythropoietin (Epo): possibly via an amelioration of renal hypoxia with stimulation of angiogenesis in the kidney. *Kidney Int*; 67: 1683-1688.
 16. **Henry RJ (1974):** Clinical chemistry. Principal and techniques. 2nd edition; p. 525.
 17. **Patton C and Crouch S (1977):** Determination of blood urea. *Anal Chem*; 49: 464.
 18. **Hissin P and Hifi R (1976):** A flurometric method for Horwitt M.K. interrelations between vitamin E and poly-unsaturated fatty acids in adult men. *Vitam Horm*; 20: 541-558.
 19. **Splittgerber A and Tappel A (1979):** Inhibition of glutathione peroxidase by cadmium. *Archives of Biochemistry and Biophysics*; 2: 534-42.
 20. **Buege J and Aust S (1978):** Microsomal lipid peroxidation. Packer L; (ed). *Methods of enzymology*. New York Acad; 52: 302-310.
 21. **Juull S, Ledbetter D, Joyce A, Dame C, Christensen R, Zhao Y and DeMarco V (2001):** Erythropoietin acts atrophic

- factor in neonatal rat intestine. *Gut*; 49: 182-189.
22. **Yang J, Liu Y (2001):** Dissection of key events in tubular epithelial to myofibroblast transition and its implications in renal interstitial fibrosis. *Am. J. Pathol.* 159, 1465–1475.
23. **Strutz F, Zeisberg M, Ziyadeh FN, Yang CQ, Kalluri R, Muller GA, Neilson EG (2002):** Role of basic fibroblast growth factor-2 in epithelial-mesenchymal transformation. *Kidney Int.* 61; 1714–1728.
24. **Atalay M, Laaksonen D, Niskanen L, Musitupa M, Hanninen O and Sen C (1997):** Altered antioxidant enzyme defenses. *Acta Physiol Scand*; 161:195-201.
25. **Vaziri ND (2004):** Oxidative stress in uremia: nature, mechanisms, and potential consequences. *Semin Nephrol.*; 24(5):469-73.
26. **Broberg AM, Grinnemo KH, Genead R, Danielsson C, Andersson AB, Wårdell E, Sylvén C (2008):** Erythropoietin has an anti apoptotic effect after myocardial infarction and stimulates in vitro aortic ring sprouting. *Biochem Biophys Res Commun.*; 371(1):75-8.
27. **Yen TH, Alison MR, Cook HT, Jeffery R, Otto WR, Wright NA, Poulson R (2007):** The cellular origin and proliferative status of regenerating renal parenchyma after mercuric chloride damage and erythropoietin treatment. *Cell Prolif.*; 40(2):143-56.
28. **Yang CW, Li C, Jung JY, Shin SJ, Choi BS, Lim SW, Sun BK, Kim YS, Kim J, Chang YS, Bang BK (2003):** Preconditioning with erythropoietin protects against subsequent ischemia-reperfusion injury in at kidney. *FASEB J.* 17, 1754–1755.
29. **Bahlmann FH, Song R, Boehm SM, Mengel M, von Wasielewski R, Lindschau C, Kirsch T, de Groot K, Laudeley R, Niemczyk E, Guler F, Menne J, Haller H, Fliser D (2004):** Low-dose therapy with the long-acting erythropoietin analogue darbepoetin alpha persistently activates endothelial Akt and attenuates progressive organ failure. *Circulation*; 110: 1006–1012.
30. **Negre O, Fusil F, Henri A, Villette JM, Leboulch P, Beuzard Y, Payen E (2008):** Activation and inhibition of the erythropoietin receptor by a membrane-anchored erythropoietin. *Exp Hematol.*; 36(4):412-23.
31. **Fenton JI, Lavigne JA, Perkins SN, Liu H, Chandramouli GV, Shih JH, Hord NG, Hursting SD (2008):** Micro array analysis reveals that leptin induces autocrine /paracrine cascades to promote survival and proliferation of colon epithelial cells in an Apc genotype-dependent fashion. *Mol Carcinog.*; 47(1):9-21.
32. **Samuni Y, Cawley NX, Zheng C, Cotrim AP, Loh YP, Baum BJ (2008):** Sorting behavior of a transgenic erythropoietin-growth

hormone fusion protein in murine salivary glands. Hum Gene Ther.; 19(3):279-86.

33. **Itoh K, Sawasaki Y, Takeuchi K, Kato S, Imai N, Kato Y, Shibata N, Kobayashi M,**

Moriguchi Y, Higuchi M, Ishihata F, Sudoh Y, Miura S (2006): Erythropoietin-induced proliferation of gastric mucosal cells. World J Gastroenterol.; 12(2):234-9.

دراسة عن تأثير الإريثروبويتين على شفاء الكلية المصابة في ذكور الفئران البيضاء

روميضاء على الشربيني- محمد نبيه عبد الرحمن
قسم الفسيولوجي و الفارماكولوجي - كلية الطب - جامعة طنطا

يهدف هذا البحث لدراسة تأثير الإريثروبويتين على الكلية المصابة بالتسمم في الفئران البيضاء. وقد أجرى هذا البحث على أربعة وعشرون فأرا قسمت لأربعة مجموعات:

- ١- المجموعة الأولى: وهي المجموعة الضابطة: وقد حققت بمحلول الملح في التجويف البريتوني.
- ٢- المجموعة الثانية: وحقنت بكلوريد الزئبق في التجويف البريتوني بجرعة واحدة تساوى ٣ مجم / كجم من وزن الجسم .
- ٣- المجموعة الثالثة: وحقنت بالاريتروبويتين في التجويف البريتوني بجرعة تساوى ١٠٠٠ وحدة/ كجم من وزن الجسم لمدة أسبوعين.

٤- المجموعة الرابعة: حقنت بكلوريد الزئبق مع الاريتروبويتين في التجويف البريتوني لمدة أسبوعين. وفي نهاية فترة البحث تم ذبح الفئران وتم تجميع عينات الدم وفصل السيرم وذلك لاستخدامه في قياس كل من : نسبة الكرياتينين في السيرم.

- ١- نسبة اليوريا في السيرم.
- ٢- تركيز الجلوتاثيون.
- ٣- نسبة انزيم الجلوتاثيون بيروكسيداز.
- ٤- المالونديالدهيد (ناتج أكسده الدهون).
- ٥- النسبة المئوية لكرات الدم الحمراء في الدم

وقد تم فتح تجويف البطن و استأصلت الكلية لأخذ عينات لفحصها مجهريا.

وقد دلت النتائج على أن كلوريد الزئبق يسبب تدهور في وظائف الكلية. فقد دلت النتائج على زيادة ملحوظة ذات دلالة إحصائية في مستوى كل من الكرياتينين واليوريا وناتج أكسده الدهون كما أظهرت النتائج انخفاض ملحوظا ذو دلالة إحصائية في مستوى الجلوتاثيون بيروكسيداز وتركيز الجلوتاثيون و نسبة كرات الدم الحمراء ، أما بالنسبة للمجموعة التي حقنت بكلوريد الزئبق و الاريتروبويتين فقد أظهرت النتائج تحسنا ملحوظا ذو دلالة إحصائية في نسبة كل من الجلوتاثيون بيروكسيداز والنسبة المئوية لكرات الدم الحمراء وأيضا تركيز الجلوتاثيون كما أن هناك نقص ملحوظ ذو دلالة إحصائية في كل من نسبة الكرياتينين واليوريا وناتج أكسده الدهون. وقد وجد من النتائج أيضا أن المجموعة التي حقنت الاريتروبويتين قد ارتفعت عندها نسبة كرات الدم الحمراء، كما أن هناك انخفاض ملحوظ ذو دلالة إحصائية في الكرياتينين وناتج أكسده الدهون . كما وجد من الفحص المجهري لعينات الكلية أن الكلية المصابة نتيجة حقن كلوريد الزئبق قد أحدث بها تآكل في النسيج الطلائى للأنايب الكلوية القريبة والبعيدة كما أن هناك اتساع في كبسولات بومان أما بالنسبة للفئران التي أعطيت كلوريد الزئبق مع الإريثروبويتين فقد ظهر تحسن ملحوظ في نمو الغشاء الطلائى للأنايب الكلوية مع اتساع بسيط في كبسولات بومان مع وجود خلايا من نخاع العظام وقليل من الاحتقان وتدل نتائج هذا البحث على أن العلاج بالاريتروبويتين قد سبب تحسن ملحوظ في وظائف الكلية المصابة كما يوصى باستعمال الاريتروبويتين لمرضى الكلية المزمنة.