

EFFECTS ON PATHOLOGICAL AND TOXICOLOGICAL ASPECTS OF NILE TILAPIA *Oreochromis niloticus* OF USING MALATHION TO ERADICATE *Lethocerus niloticum* INSECTS

Amal M. Ahmed and A.M.H. Gomaa
Regional Center for Food and Feed

ABSTRACT

Male tilapia fish (*Oreochromis niloticus*) and water bugs (*Lethocerus niloticum*) were studied in a presence of malathion (diethyldimethoxy thiophosphoryl thiosuccinate) of commercial grade 57%. Fish were fed during the experimental period once daily on a commercial dry pellet ration, while water bugs were fed on fish offales. They all were acclimatized to the same laboratory conditions for 2 weeks before the beginning of the experiment. Different malathion concentrations were experimented. The present study revealed that the minimum malathion concentration level that induced mortality of water bugs without any lethality on *Oreochromis niloticus* fish was 0.26 mg/L for 96 hrs exposure period. However, some toxic effects and histopathological alterations were observed at that condition. Gonadosomatic index, serum Testosterone, T₃ and T₄ concentration levels were determined. Brain AChE and LDH activities were also analyzed. Fish liver, spleen, gills, testes, brain and thyroid gland samples were histopathological studied.

Keywords: tilapia, water bugs, malathion, histopathological

INTRODUCTION

Water bugs (*Lethocerus* species) are commonly found in fish ponds. They normally feed on other pond life such as insect tadpoles, salamanders, small fish and snails (Huntly, 1998). Water bugs also act as a host for fish parasites (De *et al.*, 1995).

Malathion is an organophosphate insecticide that has been widely used in agricultural activities to control harmful insects (NIOSH, 1976). It was used to control invertebrate in temporary ponds in the African Sahel (Lahr *et al.*, 2008). Unfortunately, malathion seems to be toxic not only to insects but also to fish (Krueger *et al.*, 1960). Several studies were carried on fish to determine the half lethal concentration (L C₅₀) of malathion. Shim and self (2004) reported 96 hrs (L C₅₀) values for the herbivorous fish to be from 0.14 to 8.7mg/L for different organophosphorous compounds including malathion. Pathiratne and George (2007) reported that tilapia were very sensitive to malathion concentration of 2 ppm. Malathion seems to reduce the thyroid gland activity of catfish (Yadlav and Singh, 1986). It acts as a neurotoxin due to its ability to block neurotransmission by inhibiting the enzyme acetylcholinesterase (O'Brien, 1960). Hematological changes (Mishra and Srivastava, 1983) as well as histopathological changes (Walsh and Ribelin, 1975; Reddy, 1988) have also been reported. The presence of water bugs *Lethocerus niloticum* in Lake Mariut in Egypt was recorded by Sorour (2008). Therefore, this study was carried out to determine the minimum malathion concentration level that induced mortality of water bugs without any lethality

on *Oreochromis niloticus* fish. The effect of such level on gonadosomatic index, level of testosterone and the thyroid hormones, as well as the changes in the activities of brain tissue acetylcholinesterase (AChE) and lactate dehydrogenase (LDH) of tilapia has also been studied. Furthermore the histopathological alterations in the affected fish organs (liver, spleen, gills, testes, brain and thyroid gland) were also recorded at that concentration level.

MATERIALS AND METHODS

Male tilapia fish (*Oreochromis niloticus*) of 85 ± 2 g and 15 ± 1 cm length were purchased from a commercial producer (Fouky farm in Kalyobia governorate). Fish were randomly distributed in glass aquaria of 50 liter each at Abbassa research center. Dechlorinated tap water at temperature of 27 ± 2 °C with continuous oxygen supply through air pumps was used. Fish were fed during the experimental period once daily on a commercial dry pellet ration (25% protein). A 12 hrs photo period was artificially maintained. They were acclimatized to the laboratory conditions for 2 weeks before the beginning of the experiment. Water bugs (*Lethocerus niloticum*) were purchased from a local commercial specific experimental animal house producer. They were distributed and kept in glass aquaria of a same volume and under a condition similar to that of fish. Water bugs were acclimatized to the laboratory condition for 2 weeks before the beginning of the experiment and fed on fish offales during this period. Malathion (diethyldimethoxy thiophosphoryl thiosuccinate) of commercial grade 57% was used in the present study.

Five aquarium with five different malathion concentrations of 0.08, 0.17, 0.35, 0.7 and 1.4 mg/L, respectively, each was stocked with a group of ten fish. No control group (table 1, 2) was included as it is expected to have no effects on the fish or the bugs mortality. However the control group was included in studies of the hormonal and enzymes changes (table 3). Dead fish were collected and mortality percent for each group was calculated after 96 hrs (Table 1). Other five aquarium, with the same previous concentrations of malathion, each was stocked with a group of ten water bugs. Dead bugs were collected daily and mortality percent for each group was calculated after 96 hrs (Table 2).

The data of that experiment suggested that average concentration of malathion that cause death to 100% of water bugs and least mortality percent of fish was 0.26 mg/L. Therefore, another experiment was conducted to examine the effect of such concentration on gonadosomatic index, hormonal changes and enzymatic activities in brain as well as pathological changes of fish exposed to that concentration. Two groups of ten fish were stocked in two different aquariums. The first one was filled with clear water and served as control group while the other contained 0.26 mg/L malathion and considered as the test group. Five live fish were collected from each group after 24 hrs and 96 hrs, respectively, for the examination of the pathological and toxicological effects.

Gonadosomatic index was determined according to Munkittrick and Dixon (1988). Testosterone concentration in serum was determined by radioimmunoassay (RIA) according to the method of Tremblay *et al.*, (1972). On the other hand, T_3 and T_4 were determined according to the method of Brown and Eales, (1977). AChE activity in brain was determined according to Szasa (1968); while the LDH activity was determined according to the method of Annon (1971). Live fish were subjected to post-mortem examination and any lesion seen was recorded. For the histopathological study, samples from liver, spleen, gills, testes, brain and thyroid gland were fixed in 10% neutral buffered formalin, dehydrated in alcohol, cleared in xylol and embedded in paraffin. About 4 μ -thick sections were prepared and stained with Hematoxylene and Eosine (Carleton *et al.*, 1967).

Student's t-test was used to compare the significance of differences between means of control and treated groups according to Snedecor (1971).

RESULTS

The data presented in Table 2 showed that the concentration level of malathion of 0.7 mg/L caused death to 100% of the exposed water bugs. However, this concentration level caused also death to 50% of the exposed fish (Table 1). The concentration level of 0.35 mg/L caused death to 80% and 10% of water bugs and fish, respectively. On the other hand, at the 0.17 mg/L malathion neither water bugs nor fish was affected. Therefore, the present data also showed that the concentration level of malathion which caused mortality to the greatest number of water bugs and might had no lethal effect on tilapia lies between the concentration levels of 0.17 and 0.35 mg/L. Therefore, an average concentration of malathion of 0.26 mg/L may be recommended in the present work to be effectively used in eradicating water bugs in tilapia ponds.

The effect of the average concentration level on gonadosomatic index was presented in Table (3). No significant ($P < 0.05$) decrease in the gonadosomatic index after 24 hrs (0.013 ± 0.0004) was observed compared to the control group (0.014 ± 0.0002). On contrary, the same index showed significant ($P < 0.05$) decrease (0.012 ± 0.001) after 96 hrs compared with control group.

The effect of the average concentration level on the testosterone and thyroid hormones is presented in Table (3). There was a significant ($P < 0.05$) decrease in testosterone level (79.2 ± 1.68) after 96 hrs exposure period compared with the control group (81.4 ± 1.97). Similar trend was recorded for the thyroid hormones levels (T_3 & T_4) i.e. significant ($P < 0.05$) decrease (62.76 ± 1.08 and 1.82 ± 0.025 , respectively) after the same period of exposure, compared with the control group (64.62 ± 0.49 and 2.30 ± 0.02 , respectively). Moreover, the levels of hormones showed no significant decrease during 24 hrs exposure to malathion.

These results showed no significant ($P < 0.05$) changes in both AChE and LDH activities of brain tissue at 24 hrs exposure period. While induced significant inhibition in the activities of fish AChE and lactate LDH in the brain

tissue at 96 hrs where the values being 64.0 ± 1.41 and 59.6 ± 0.89 u/L, respectively, in comparison to the control values, 68.0 ± 0.31 and 61.2 ± 1.24 u/L, respectively, (Table, 3).

Histopathological examination of fish treated with 0.26 mg/L malathion for 24 hrs revealed no alterations in examined organs especially testes and thyroid gland (Fig. 1, 2).

The gross examination of fish exposed to the average concentration level (0.26 mg malathion/ L) for 96 hrs revealed abnormal black discoloration of the body, severely congested gills and rough scales. The histopathological examination of such group showed the apparent changes. In the liver, vacuolar degeneration of the hepatocytes and severe congestion of hepatoportal blood vessels were observed (Fig. 3). Mononuclear cell infiltration was noticed in portal area and around the hepatoportal blood vessels. In such cases, mild degenerative changes were seen in hepatopancreatic region. In other cases, histopathological examination showed mild pathological alterations including congestion of the hepatic blood vessels and granular degeneration of some hepatocytes. The examination of spleen revealed depletion of lymphocytes with decreased melanin intensity of melanomacrophage centers (Fig. 4). In other cases, splenic ellepsoids showed marked thickening of their capillary wall, swelling of the endothelial lining with activation of the haematopoietic cells around the blood vessels of the ellepsoids (Fig. 5). The examined gills revealed severe congestion of the lamellar capillaries (Fig. 6), while in other fish, gill oedema and aggregation of eosinophilic granular cells (EGC) was the common picture (Fig. 7). In other cases, hyperplasia of the cells constituting gill lamellae together with fusion of secondary lamellae was a common lesion observed (Fig. 8). The examined testes of this group showed degeneration and atrophy of the germinal epithelium of seminiferous tubules and a few spermatozoa in their lumen (Fig. 9). The brain of the fish in this group showed focal gliosis with oedema (Fig. 10). Thyroid gland examination revealed devoidence of some follicles from colloid (Fig. 11), but without evidence of cellular hyperplasia.

DISCUSSION

The present results revealed that the 96 hrs LC_{50} of malathion was 0.70 mg/L. Shim and Self (2004) reported 96 hrs LC_{50} values for the herbivorous fish to be from 0.14 to 9.7 mg/L for different organophosphorous compounds including malathion. Shukla *et al.*, (2002) determined the LC_{50} of malathion for the fingerlings of *Channa punctatus* and found it was in the range of 10.95 to 3.22 mg/L for 24 to 96 hrs exposure periods. Jagan *et al.*, (1989) recorded the LC_{50} of malathion for carp fish (*Cyprinus carpio*) to be 0.138 ppm. Tsuda *et al.* (1997) determined the 48 hrs LC_{50} for malathion in Killfish to be 1.8 mg/L. Pathiratne and George (2007) reported that tilapia were very sensitive to malathion (96 hrs $LC_{50} = 2$ ppm). Variation between the present results concerning the estimation of LC_{50} of malathion and those of other investigators may be attributed to several factors such as species, age,

body weight, time of exposure, the method used and the sensitivity of fish as well as stress factors. Concerning the reduction of gonadosomatic index of fish exposed to malathion the present results were in agreement with the findings reported by many investigators. Haider and Upadhyaya (2005) found that the commercial formulation of four organophosphorous insecticides birlane, jardona, phosdrin and malathion caused loss of stage II and III oocytes

Table (1) Mortality data of *Oreochromis niloticus* fish exposed to different concentration levels of malathion

Fish Group	Fish/group	Dose mg/L	Dead fish	Mortality %
1 st	10	0.08	0	0
2 nd	10	0.17	0	0
3 rd	10	0.35	1	10
4 th	10	0.70	5	50
5 th	10	1.40	6	60

Table(2):Mortality data of water bugs exposed to different concentration levels of malathion

Water bugs Group	Water bugs /group	Dose mg/L	Dead water bugs	Mortality %
1 st	10	0.08	0	0
2 nd	10	0.17	0	0
3 rd	10	0.35	8	80
4 th	10	0.70	10	100
5 th	10	1.40	10	100

Table (3) Effect of average concentration level of malathion on gonadosomatic index, some hormonal and enzymatic activities of *Oreochromis niloticus*

	Control Zero Malathion		Treatment 0.26 mg/L. Malathion	
	24 h.	96 h.	24 h.	96 h.
Gonado somatic index %	0.014 ± .0002	0.014 ± 0.0002	0.013 ± 0.0004	0.012* ± 0.0001
Testosterone ng/dL	81.4 ± 1.97	81.4 ± 1.97	81.0 ± 0.97	79.2* ± 1.68
Triiodothyronine T ₃ ng/dL	65.5 ± 0.15	64.6 ± 0.49	63.0 ± 1.12	62.7* ± 1.08
Thyroxin T ₄ ng/dL	2.3 ± 0.01	2.3 ± 0.02	2.28 ± 0.03	1.82* ± 0.02
Actylcholin esterase ACHE u/L	68.0 ± 0.31	68.0 ± 0.31	65.8 ± 1.59	64.0* ± 1.41
Lactate dehydro genase LDH u/L	61.2 ± 1.24	61.2 ± 1.24	59.8 ± 0.97	59.6* ± 0.98

*Significant at p< 0.05

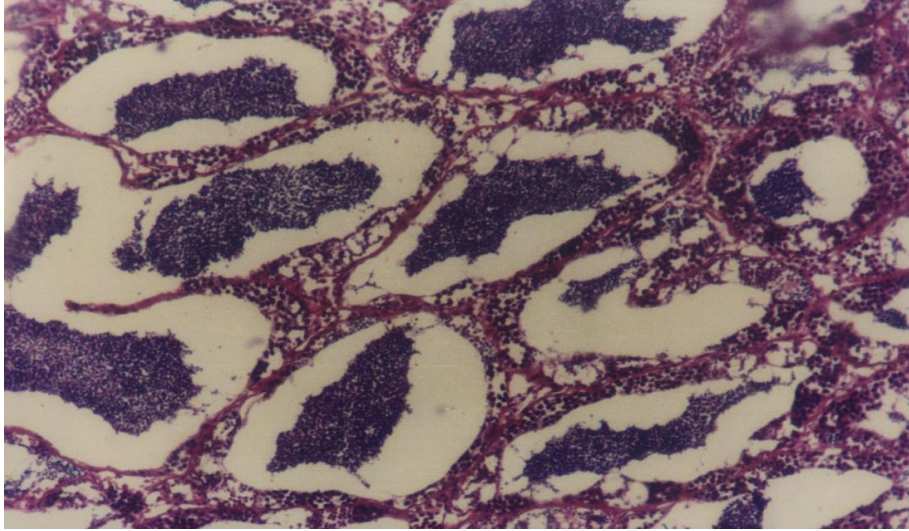


Fig. (1): Testis of *Oreochromis niloticus* fish exposed to 0.26 mg/L malathion for 24-h, showing normal seminiferous tubules impacted with spermatozoa. [H&E stain, X40]

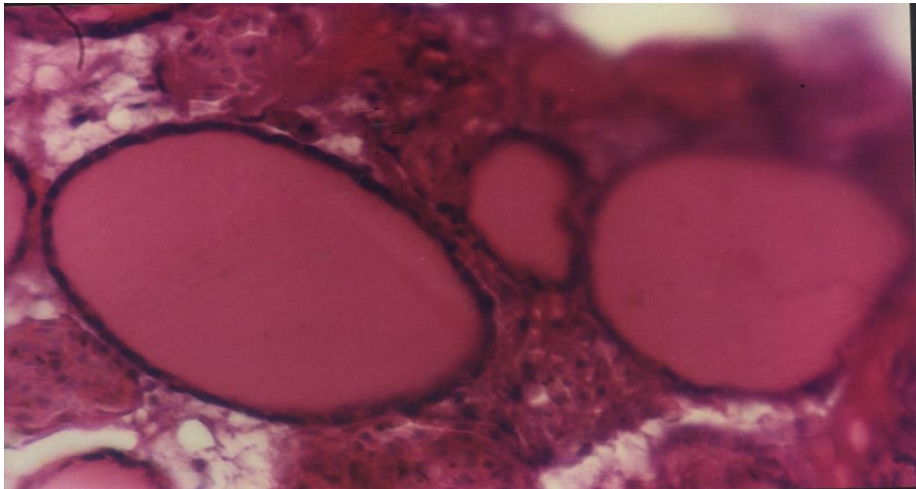


Fig. (2): Thyroid gland of *Oreochromis niloticus* fish exposed to 0.26 mg/L malathion for 24-h, showing normal follicles. [H&E stain, X40]

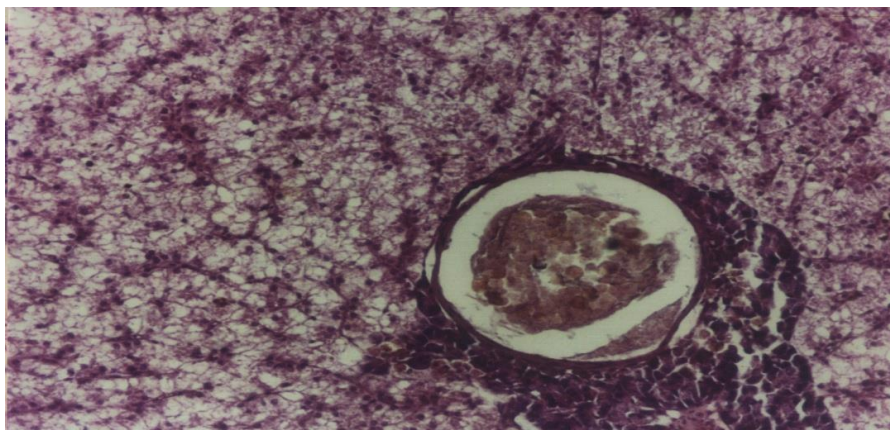


Fig. (3): Liver of *Oreochromis niloticus* fish exposed to 0.26 mg/L malathion for 96-h, showing vacuolar degeneration of the hepatocytes and severe congestion of hepatportal blood vessels. [H&E stain, X40]

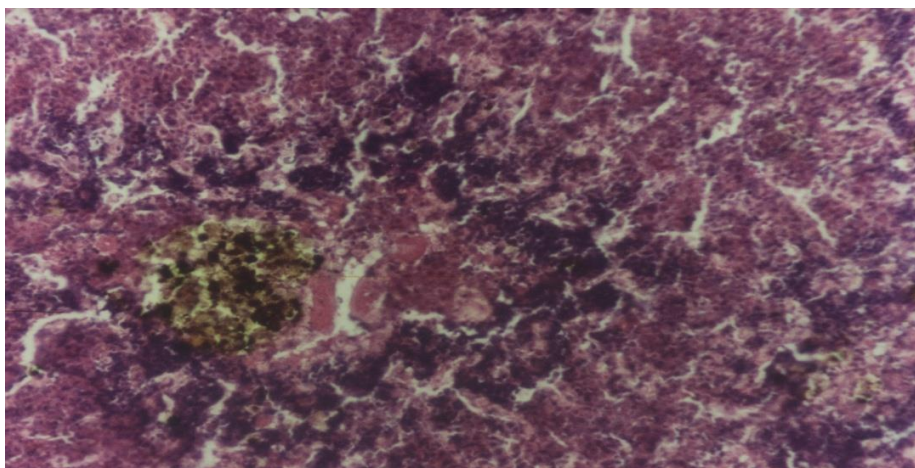


Fig. (4): Spleen of *Oreochromis niloticus* fish exposed to 0.26 mg/L malathion for 96-h, showing lymphocytic depletion and melanomacrophage center devoid of melanin. [H&E stain, X40]

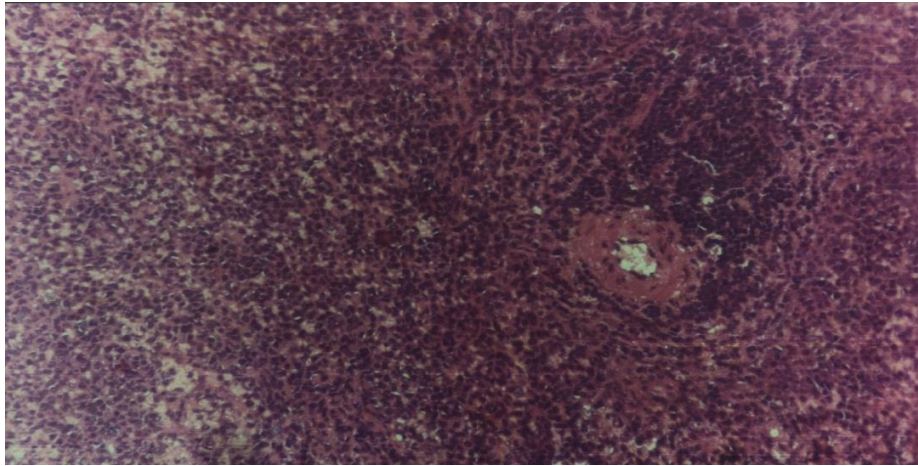


Fig. (5): Spleen of *Oreochromis niloticus* fish exposed to 0.26 mg/L malathion for 96-h, showing swelling of endothelial cells of ellipsoidal capillaries (arrow), thickening of capillary wall and activation of hemopoietic element. [H&E stain, X40]

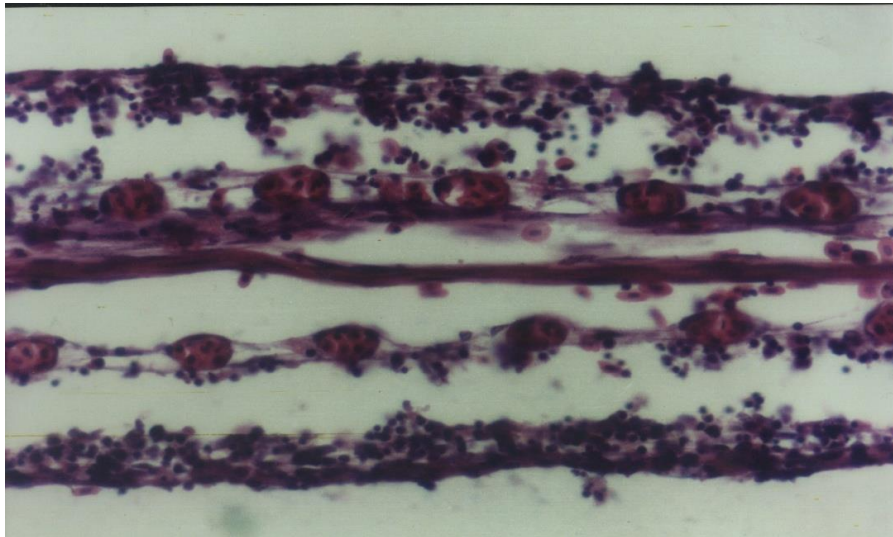


Fig. (6): Gills of *Oreochromis niloticus* fish exposed to 0.26 mg/L malathion for 96-h, showing severe lamellar capillary congestion. [H&E stain, X40]

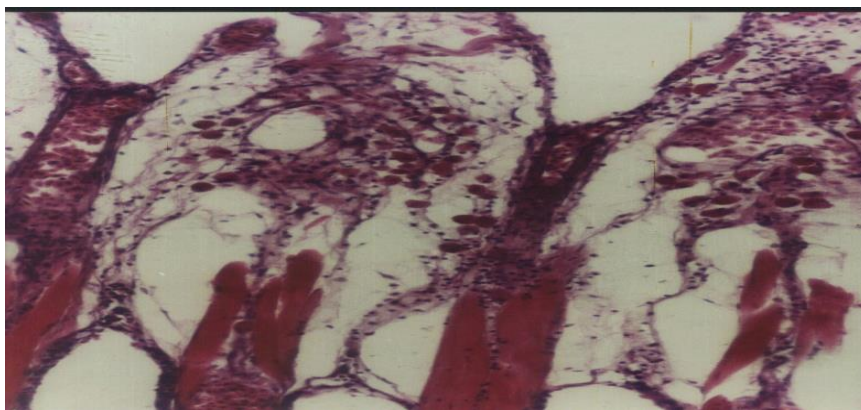


Fig. (7): Gills of *Oreochromis niloticus* fish exposed to 0.26 mg/L malathion for 96-h, showing oedema and eosinophilic granular cells infiltration. [H&E stain, X40]

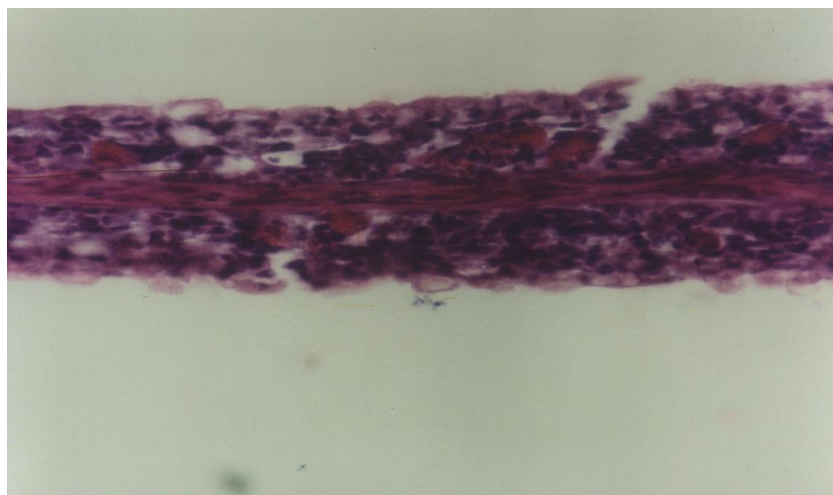


Fig. (8): Gills of *Oreochromis niloticus* fish exposed to 0.26 mg/L malathion for 96-h, showing hyperplasia and fusion of secondary lamellae. Notice: mucous secreting cells activation and eosinophilic granular cell aggregation. [H&E stain, X40]

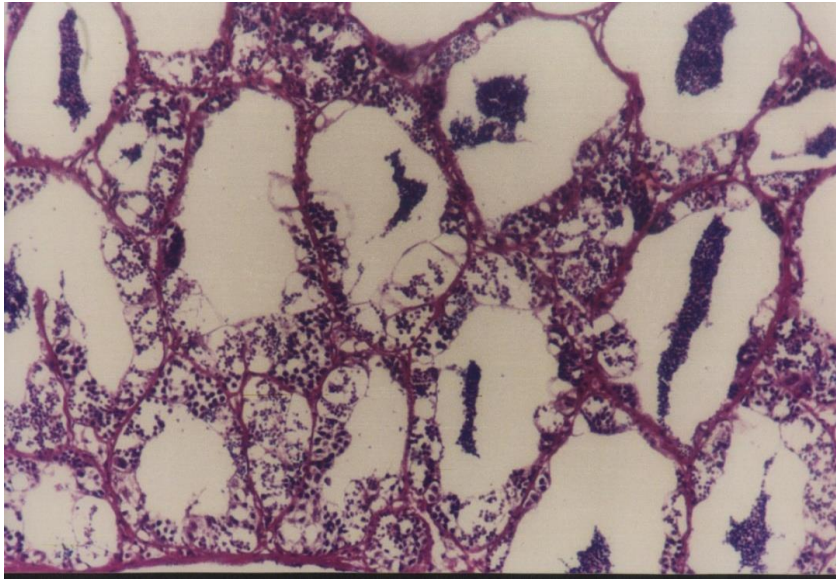


Fig. (9): Testis of *Oreochromis niloticus* fish exposed to 0.26 mg/L malathion for 96-h, showing degeneration of germinal epithelium. Notice: the seminiferous tubules are devoid of spermatozoa. [H&E stain, X40]

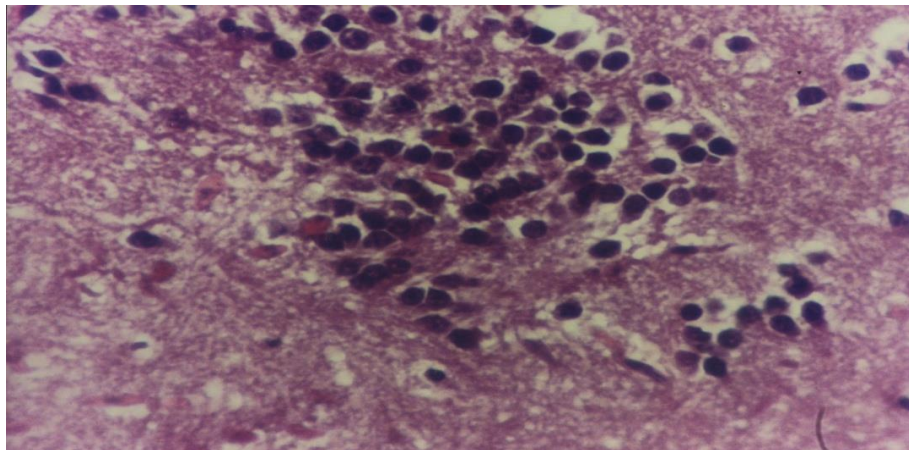


Fig. (10): Brain of *Oreochromis niloticus* fish exposed to 0.26 mg/L malathion for 96-h, showing focal gliosis. [H&E stain, X40]

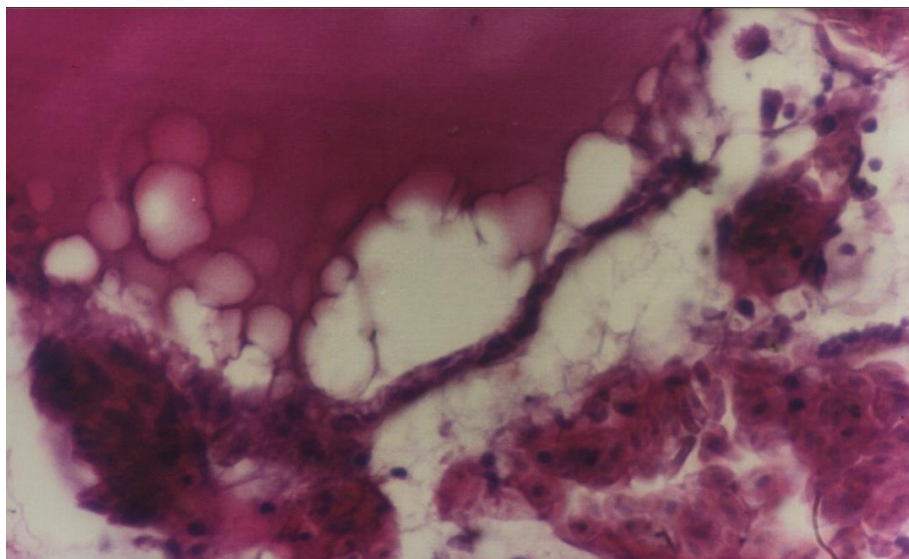


Fig. (11): Thyroid gland of *Oreochromis niloticus* fish exposed to 0.26 mg/L malathion for 96-h, showing colloid devoid in the lumen of thyroid follicle. [H&E stain, X40]

accompanied by significant decline in gonadosomatic index of fresh water teleost, *Mystus vittatus* (bloch) exposed to malathion. Shukla *et al.*, (2002) reported that the sublethal concentration of malathion had adverse effects on growth and metabolism, and exposure of fingerling *Channa punctatus* fish to 2.5 mg/L malathion induced significant reduction in growth. Khillare and Wagh (1988) showed that the fish *Puntius stigma* collected from the river Kham Aurangabad, India showed changes in survival, feeding, growth rate and oxygen consumption during chronic exposure to endosulfan, malathion and sevin (carbaryl). Ramakrishnan *et al.* (1997) exposed the *Oreochromis mossambicus* to the sublethal concentration of malathion (0.3-1.2 ppm).

The present results showed significant ($P < 0.05$) reduction in the testosterone level of 96 hrs malathion exposed fish. This decrease is supported by the histopathological findings of the affected testes. There was marked degeneration and atrophy of the germinal epithelium of the seminiferous tubules with a few spermatogonia in their luminae. Several researches proved that some types of pesticides as organophosphates, pyrethroids, fungicides and herbicides may possess antiandrogenic effect in different livestock (Brody *et al.*, 1983; Eil and Nisula, 1990 and Wolf *et al.*, 2003). They also showed that pesticides can interact competitively with androgen receptors and sex hormones binding globulin, a mechanism by which exposure to pesticides may result in disturbances in endocrine effect related to androgen action. Singh and Singh (1987) studied the effect of

cythion (organophosphorous) and BHC (organochlorine) on the level of sex hormones (testosterone, estradiol-17 beta and estrone) in catfish *Clarias batrachus*. Sublethal concentrations of either pesticide apparently affected sex hormones production after 4 weeks of exposure, as was evident by the decrease of their levels in blood plasma. They suggested that cythion and BHC toxicity affected sex hormones production due to the impairment in the synthesis and/or release of these steroids. In the present investigation, the reduced serum T_3 & T_4 levels in 96-hours exposed fish clearly indicated altered thyroid function. These results were in agreement with those of Sinha *et al.*, (1991) and Aktar *et al.* (1996). Sinha *et al.*, (1991) concluded that malathion decreased the level of T_3 & T_4 and T_3/T_4 ratio in *Clarias batrachus* fish without altering the level of T_4 in blood circulation. Aktar *et al.*, (1996) exposed rats to malathion and observed that malathion induced significant decrease in serum concentration of T_3 & T_4 . The reduced T_4 level by malathion might be due to the sequential retardation of iodine accumulation and its conversion into hormonal form i.e. hormone biosynthesis (Singh and Singh, 1980). Leatherland and Sonstegard (1978) reported significant reduction in the levels of both T_3 & T_4 in *Oncorhynchus kaisutch* fed with an organophosphorous, mirex. They suggested that the extrathyroidal conversion of T_4 to T_3 was inhibited. The present results demonstrated clearly that malathion had an inhibitory effect on biosynthesis of T_4 and the extrathyroidal conversion of T_4 to T_3 .

Inhibition of AChE activity in fish brain after exposure to organophosphorous pesticides is very specific effect, which can be utilized for diagnostic purposes. This inhibitory effect has been taken as an index of organophosphorous insecticide toxicity (Chakraborty *et al.*, 1978). The inhibition of AChE was maximal in the brain, muscles and gill (Nagat Ali, 1995). The inhibition of AChE activity reported in the present study was in agreement with Ansari and Kumar (1984); Johnson and Wallace (1987); Sulaiman *et al.*, (1989); Nemcsok *et al.*, (1990).

Ansari and Kumar (1984) reported that a 7-day exposure to 0.5-1.1 mg/L malathion significantly inhibited the brain AChE activity in the zebra fish (*Brachydanio rerio*). Johnson and Wallace (1987) recorded that malathion caused inhibition of brain AChE activity in fat head minnows and rainbow trout. Sulaiman *et al.* (1989) mentioned that AChE activity of the brain was depressed significantly in *Tilapia nilotica* and *Tilapia mossambica* exposed to malathion. Nemcsok *et al.* (1990) studied the In-vivo effect of 2 ppm of malathion on the carp (*Cyprinus carpio*) brain and liver AChE. They found that the enzyme activity decreased significantly in the examined tissues. The inhibition of AChE of brain was a dose-dependent Das and Sengupta (2003). Beauvais *et al.* (2000) reported that AChE activity was significantly decreased with increasing the concentration of malathion and significantly differed among exposure durations.

The present results showed that the brain LDH activity was significantly reduced in the treated fish than control group. These findings was confirmed by the histopathological examinations in the present study since the brain showed focal gliosis and oedema. These results were in agreement with those of Rani *et al.*, (1990). They also exposed *Clarias batrachus* fish to

malathion at 5 ppm for 96 hrs. The results indicated reduction in the activity of LDH in liver, gills and brain. LDH has a role for interconversion of lactate and pyruvate in the presence of NADH and NADH₂. Reduction of LDH activity in brain tissues or other tissues indicated tissue damage to the affected organs with elevation in serum LDH activity (Murray *et al.*, 1988).

Our findings revealed that *Oreochromis niloticus* exposed to malathion resulted in marked histopathological findings in the liver, spleen, gills, tests, brain and thyroid gland of the tested fish. The histopathological alterations in the liver of treated fish were in agreement with the findings reported by Anees (1978); Ramalingam (1988) and Al-Hamdanne (1998). Anees (1978) stated that malathion caused vacuolation and necrosis of hepatocytes in channel catfish. Ramalingam, (1988) reported that malathion caused comparatively more liver damage of fish *Sarotherodon mossambicus* than mercury and several changes such as necrosis, fatty degeneration and also red cell occlusion in portal vessels were observed. Several histopathological changes in carp fish exposed to malathion were recorded by Al-Hamdanne (1998). These changes include vacuolation of hepatic cells with sinusoidal congestion, kidney congestion, haemorrhage of intestinal submucosal layer and coagulative necrosis of muscles. Regarding the histopathological changes in the spleen of malathion-treated fish; Abu-Hadeed (1978) exposed Nile catfish (*Clarias lazera*) to the organophosphorous insecticide (Curacron) and his results revealed severe congestion and destruction of some lymphoid follicles of spleen. Similar findings were reported by Abou El-Magd *et al.*, (1998) who observed congestion, moderate depletion of the lymphocytes of the splenic white pulp, thickening of splenic blood vessels, activation of the melanomacrophage centers and infiltration of the red pulp with lymphocytes in Nile catfish treated with glyphosate. Our results were almost similar to those recorded by Hussain (1993) who showed depletion of the lymphocytes in the white pulp of spleen in rats treated with some pesticides. Marked histopathological lesions in the gills of *Oreochromis niloticus* fish exposed to malathion were observed in the present study. Several investigators reported similar alterations in the gills of the affected fish. Walsh and Ribelin (1975) for instance mentioned that malathion caused lesions in the gills of exposed fish including necrosis, hyperplasia, hypertrophy and oedema. Reddy (1988) showed also that sublethal concentration of malathion (2 ppm) damage to the gill architecture in carp fish after 15 days from exposure. He also reported that this damage decreased rates of O₂ consumption rates and opercular movement of fish.

In conclusion the present study revealed that the minimum calculated malathion concentration level that may induce mortality of water bugs without any lethality on *Oreochromis niloticus* fish was estimated at 0.26 mg/L for 96 hrs exposure period. However, some toxic effects and histopathological alterations were practically observed at that level. Therefore further studies are needed to verify the optimum level of malathion that could be used to eradicate *Lethocerus niloticum* without any adverse effects on the tilapia fish or human safety.

REFERENCES

- Abou El- Magd, M. M; H. G. Mervat; and S. D. Ahmed (1998): Some toxicological aspects of glyphosate [Round-up] herbicide on Nile catfish [*Clarias lazera*] . *a Zag . vet .J.26(1)15-24*.
- Abu-Hadeed , A. H. (1978) : Some toxicological studies of organophosphorus insecticide [curacron] to Nile fish *Clarias lazera*. M.V.Sc. Thesis Faculty of vet. Med . Zagazig university.
- A., Kayani, M. M. Ahmad, and M. Shahab, (1996) : insecticide-induced changes in secretory activity of the thyroid gland in rats. *J. Appl. Toxicol.*, 16 (5397-400).
- Al-Hamdanne, A. H. (1998) : Pathological study of malathion toxicity in the common carp [*Cyprinus carpio L.*] . *Iraqi- J. Vet. [Sci., 11 (1): 39 – 44 .*
- Anees, M. A. (1978) : Hepatic pathology in a freshwater teleost *Channa punctatus* (Bloch) exposed to sublethal and chronic levels of three organophosphorus insecticides. *Bull, Environ. Contam. Taxicol ., 19 : 524 – 527 .*
- Annon, L. (1971) : Photometric determination of LDH activity in blood serum. *Z . Klin . Chem. Klin. Biochem., 8 : 658*.
- Ansari , B. A. and K. Kumar, (1984) : Malathion toxicity : In vivo inhibition of acetylcholinesterase in the fish, *Brachydanio rerio* [*Cyprinidae*] . *Toxicol. Lett ., 20 : 283 .*
- Asztalos, B. and J. Nemcsòk, (1985) : Effect of pesticides on the LDH activity and isoenzyme pattern of carp [*Cyprinus carpio L.*] sera. *Comp. Biochem. Physiol., 82C : 217-219 .*
- Beauvais , S. L., S. B., Jones, S. K. Brewer, and E. Little, (2000) : Physiological measures of neurotoxicity of diazinon and malathion to larval rainbow trout [*Oncorhynchus mykiss*] and their correlation with behavioral measures. *Environ. Toxicol . chem., 19 (7) : 1875 – 1880 .*
- Brody, S. A., J. Winterer; M. A. Drum, K. Barrns, C. Eil and D.L. Loriaux (1983) : An epidemic of gynecomatstia in Haitian refugees : Possible exposure to an anti-androgen. Program and Abstracts of the 65 th Annual Meeting of the Endocrine Society. San Antinio, Tex., June , Abst. 724 , P. 261.
- Brown , S. and J. G. Eales , (1977) : Measurement of L-Thyroxine and 3,5,3 – triodo-L- thyronine levels in fish plasma by radioimmuno assay. *Canad . J. Zool, 55, 293-299*.
- Carleton , M., R.A. Drury , E. A. Wallington, and C. Sir Roy, (1967): [*Carleton's Histological Technique*] 4th .ed. London, Oxford University, Press, New York, Toronto .
- Chakraborty, D., A. Bhattacharyya, K. Majumdar, K. Chatterjee, S. Chatterjee, A. Sen. and G. C. Chatterjee (1978) : Studies on L-ascorbic acid metabolism in rats under chronic toxicity due to organophosphorus insecticides : effects of supplementation of L-ascorbic acid in high doses. *J. Nutr., 108 (6) : 973 – 980 .*

- Das, R.C. and B. Sengupta, (2003) : Effect of endosulfan and malathion on the ovarian steroidogenesis and brain acetylcholinesterase activity of the catfish , *Clarias batrachus* [Linnaeus] . *Veterinarski-Arhiv.*, 63 (2) : 75-83.
- De. A., S. K. Banerjee, P. Das , and A. Bhattacharya, (1995) : Isolation , cultivation and partial characterization of a kinetoplastid flagellate from the hindgut of the water bug, *Lethocerus indicus*. *Microbios*, 83 (334) : 49-57.
- Eil , C. and B. C. Nisula (1990) : The binding properties of pyrethroids to skin fibroblasts androgen receptors and to sex hormone binding globulin. *J. Steroid Biochem.*, 35 (3-4) : 409 .
- Haider, S. and N. Upadhyaya, (2005) : Effect of commercial formulation of four organophosphorus insecticides on the ovaries of a freshwater teleost, *Mystus vittatus* (Bloch) – a histological and histochemical study. *J. Environ. Sci. Health B*, 20 (3) : 321-340.
- Huntley , A. (1998) : *Lethocerus americanus* , the “ toe biter” . *Dermatol Online*, 4 (1) : 6 .
- Hussain, S. H. (1993) : Experimental pathological studies of some pesticides induced through transplacental transmission in albino rats. M. V. Sc. Thesis. Faculty of vet . Med. Zagazig University .
- Jagan, P., M.S. Reddy and A.p. Rao (1989) : Effect of certain insecticides on the freshwater fish *Cyprinus carpio carpio*, L . *Journal of Environmental Biology*, 10 (2) : 135-138.
- Johnson, J.A. and K. B. Wallace (1987) : Species –related differences in the inhibition of brain acetylcholinesterase by paraoxon and malaoxon. *Toxicol. Appl. Pharmacol .*, 88 : 234-241 .
- Khillare, Y. K. and S. B. Wagh (1988) : Long-term effects of pesticides endosulfan, malathion and sevin on the fish *puntius stigma*. *Environmental and Ecology*, 6 (3) : 589-593.
- Krueger, H. R., R. D. O'Brien, and W.C. Dauterman (1960) : Relationship between metabolism and differential toxicity in insects and mice of diazinon, dimethoate, parathion and acethion. *Econ. Entomol.*, 53 : 25-31.
- Lahr , J; A. Badji, S.Marquenie, E.Schuling, k.B. Ndour ;A.O. Diallo. and J.W.Everts, (2008) : Acute toxicity of locust insecticides to two indigenous invertebrates from Sahelian temporary ponds. *Ecotoxicol. Environ. Saf .* 48 (1) : 66-75 .
- Leatherland , J. F. and R.A. Sonstegard, (1978) : Lowering of serum thyroxine and triiodothyronine levels in yearling coho salmon, *Oncorhynchus kisutch*, by dietary mirex and PCBs. *J. Fish Res. Board Canad.*, 35 : 1285 – 1289 .
- Mishra, J. and A.K. Srivastava, (1983) : Malathion induced hematological and biochemical changes in the Indian catfish *Heteropneustes fossilis* . *Environ. Res.*, 30 : 399 – 411 .
- Munkittrick, R. and G. Dixon , (1988) : Growth, fecundity and energy stores of white sucker from lakes containing elevated levels of copper and zinc. *Can.J. Fish . Aquat. Sci .*, 45 : 1355-1365 .

- Murray, R. K., D. K., Granner, P.A. Mayes, and V.W. Rodwell, (1988) : Harper's Biochemistry . 2nd . Ed. Appleton & Lange Norwalk , Connecticut Los Altos-California p. 656 .
- Nagat , M. A. (1995) : Interaction of pesticides with biological processes in aquatic organisms. Ph. D. Thesis , Faculty of Agriculture , Alexandria University.
- Nemcsók, J., Z. Rakoncjay, P. Kasa; B. Asztalos , and A. Szabo, (1990) : Effects of methidathion on distribution of molecular forms of acetylcholinesterase in carp, as revealed by density gradient centrifugation. *Pest . Biochem . Physiol.*, 37 (2) : 140 –144
- National Institute of Occupational Safety and Health [NIOSH] (1976) : "Criteria for a Recommended Standard. "Occupational Exposure to Malathion , " NJOSH Document No. 76-205. National Institute of Occupational Safety and Health , U. S. Department of Health, Education and Welfare, Washington, D.C.
- O' Brien, R. D. (1960) : Toxic phosphorus esters. Academic Press New York.
- Pathiratne, A. and S.G. George (2007) : Toxicity of malathion to Nile tilapia, *Oreochromis niloticus* and modulation by other environmental contaminants. *Aquatic Toxicology*, 43 (4) : 261 – 271 .
- Ramakrishnan, M; S. Arunachalam and S. palanichamy (1997) : Sublethal effects of pesticides on physiological energetics of freshwater fish, *Oreochromis mossambicus*. *Journal of Ecotoxicology and Environmental Monitoring*, 7 (4) : 237-242 .
- Ramalingam ,K. (1988) : Effects of DDT , malathion and mercury on the liver histomorphology of the fish *Sarotherodon mossambicus*. *Environment and Ecology* , 6 (3) : 761 – 762 .
- Rani, V. J. S; P. Venkateshwarlu. and C. Janaiah (1990) : Impact of sublethal concentration of malathion on certain aspects of metabolism in freshwater fish , *Clarias batrachus* [Linn.] *Comparative –Physiology and Ecology*, 15 (1) : 13-16.
- Reddy , P. M. (1988) : Effect of malathion on the oxygen consumption and rate of opercular movement of *Cyprinus carpio* . *Geobios*, 15 (1) : 7 – 10 .
- Shim, J. C. and L.S. Self (2004) : Toxicity of agricultural chemical to larvivorous fish in Korean rice fields. *Pest . Abs.*, 7 : 1874-1888.
- Shukla, J. p., M. Banerjee- and K. Pandey (2002) : Deleterious effects of malathion on survival and growth of the fingerlings of *Channa punctatus* [Bloch.] , a freshwater murrel. *Acta-Hydrochimica-et-Hydrobiologica*. 15 (6) : 653-657.
- Sinha, N; B. Lal and T.P. Singh (1991) : Pesticides induced changes in circulating thyroid hormones in the freshwater catfish *Clarias batrachus*. *Comp. Biochem. Physiol.*, 100c (1-2) : 107-110 .
- Singh, H. and T.P. Singh (1987) : Thyroid activity and TSH potency of the pituitary gland and blood serum in response to cythion and hexadron treatment in the freshwater catfish, *Heteropneustes fossilis* [Bloch] *Environ. Res*, 22 : 184-189.

- Singh, S. and T.P. Singh (1987) : Evaluation of toxicity limit and sex hormone production in response to cythion and BHC in the vitellogenic catfish *Clarias batrachus*. *Environ. Res.*, 42 (2) : 482 .
- Snedecor, G. W. (1971) : [*Statistical Methods*] . 6 th. Ed. PP : 59 – 65. Ames , Iowa, the Iowa State Univ. Press.
- Sulaiman, A. H., A.R. Abullah and S.H. Ahmed (1989) : Toxicity of malathion to red tilapia hybrid [*Tilapia mossambica*, *Tilapia nilotica*] : Behavioal, histopathological and anticholinesterase studies . *Malaysian Applied Biology* , 18 (2) : 163-170 .
- Szasa, G. (1968) : Cholinestrse determinations in serum with acetyle and Butyryl thiocholine as substrate. *Clin. Chem. Acta*, 19 : 191 – 204 .
- Sorour , J (2008) : Ultrastructural variations in *Lethocerus niloticum* (Insecta : Hemiptera) caused by pollution in Lake Mariut , Alexandria , Egypt. *Ecotoxicol. Environ. Saf.*, 48 (3) : 268-274 .
- Tsuda, T., M. Kojima, H. Harada ,A. Nakajma , and S. Aoki (1997) : Acute toxicity , accumulation and their oxidation products in Killifish. *Chemosphere*, 35 (5) : 939-949
- Tremblay, R. R. ,T. O. Jr. Foley; P. Corvol ; J.J. Park ,A. kowarski, R.M. Blizzard H. W. Jr. Jones and C.J. Migeon (1972) : Plasma concentration of testosterone , dihydrotestosterone, testosterone – Oestradiol binding globulin and pituitary gonadotrophins in the syndrome of male pseudohermaphroditism with testicular feminization *Acta Endocrinol .*, 70 : 331 – 341 .
- Walsh , A.H. and W.E. Ribelin. (1975): The pathology of pesticide poisoning. PP. 515 –537. In : Ribelin, W.E. and Migaki, G (ed.) *The pathology of fishes*. The University of Wisconsin Press, Madison , Wisconsin .
- Wolf . C.J.; G.A. Le Blanc, J.S. Ostby , and L.E.Jr. Gray (2003) : Characterizaion of the period of sensitivity of fetal male sexual development to vincolzolin. *Toxico. Sci.* , 55: 152-161.
- Yadav , A.K. and T.P. Singh (1986) : Effect of pesticide on circulating thyroid hormone levels in the freshwater catfish, *Heteropneustes fossilis* (Bloch). *Environ. Res.*, 39 (1) : 136-142.

تأثيرات سمية وباثولوجية على أسماك البلطي النيلي عند استخدام الملاثيون لإبادة
حشرة بق الماء
أمل مصطفى أحمد و اشرف هاشم جمعة
المركز الاقليمي للأغذية والأعلاف بمركز البحوث الزراعية .

يعتبر وجود بق الماء (ليثوسيرس النيلي) في أحواض الأسماك من الخطورة حيث أنه يتغذى على الأسماك وعليه يهدف هذا البحث إلى تحديد جرعة المبيد الحشري الفوسفوري ملاثيون التي تسبب نفوق لبق الماء دون أى تأثير عكسي على الأسماك . لتحقيق ذلك الهدف تم تعريض ذكور أسماك البلطي النيلي إلى جرعات مختلفة من الملاثيون لتحديد التركيز نصف المميت للأسماك . ومن ناحية أخرى تم تعريض بق الماء (ليثوسيرس النيلي) إلى نفس الجرعات لمعرفة نسبة النفوق الحادثة في بق الماء عند التعرض لهذه الجرعات . ومن نتائج التجريبتين السابقتين يمكن تحديد مستوى الجرعة من الملاثيون الذي يسبب نفوق في بق الماء دون حدوث نفوق للأسماك . هذا وقد تم تعريض مجموعة أخرى من الأسماك وبق الماء إلى هذه الجرعة لمدة ٢٤ ساعة و ٩٦ ساعة لدراسة التأثير السام وكذلك التأثير الهستوباثولوجي على أنسجة الأسماك المعرضة لهذه الجرعة . هذا وقد تم تحديد معامل وزن الخصية إلى الجسم وكذلك بعض هرمونات السيرم مثل التستوستيرون والتراى أيبودو ثيرونين (تى ٣) والثيرونكسين (تى ٤) وأيضاً النشاط الأنزيمي لبعض خمائر إنسجة المخ مثل الكولين استيريز واللاكتات ديهيدروجيناز . وقد أوضحت الدراسة أن التركيز نصف المميت للملاثيون هو ٠.٧٠ مجم / لتر من الماء بينما مستوى الجرعة الأيمن من الملاثيون الذي يسبب نفوق لبق الماء ولا يسبب نفوق للأسماك هو ٠.٢٦ مجم / لتر . أيضاً هناك نقص معنوي في معامل وزن الخصية بالنسبة للجسم بعد ٩٦ ساعة من التعرض مع نقص في مستوى الهرمون بالسيرم وكذلك تثبيط لنشاط خمائر أنسجة المخ . وقد دعمت هذه النتائج بالدراسة الهستوباثولوجيا والتي أوضحت وجود تغيرات باثولوجية بجميع الأنسجة التي تم دراستها بعد هذه الفترة من التعرض لهذه الجرعة . ومن التحليل الاحصائي لهذه النتائج وجد أن مستوى الجرعة الأيمن من الملاثيون للأسماك والفعال في إبادة بق الماء هو ٢٦ مجم / لتر ويطبق لمدة ٢٤ ساعة فقط حيث أنه لا يوجد أي تأثير عكسي لهذه الجرعة على الأسماك خلال هذه الفترة من التعرض .