

**ULTRASTRUCTURE OF SARCOCYSTIS BUFFALONIS
(HUONG ET AL., 1997) INFECTING WATER BUFFALOES
(BUBALUS BUBALIS) FROM EGYPT**

BY

Abu-Elwafa, S. A; Abbas, I. E. A. and Alaraby, M. A.

*Parasitology Department, Faculty of Veterinary Medicine, Mansoura University,
35516, Mansoura, Egypt.*

ABSTRACT

Water buffaloes are infected with four *Sarcocystis* species, the macroscopic *S. fusiformis* and *S. buffalonis*, and the microscopic *S. levinei* and *S. dubeyi*. Few reports conducted on the presence of the newly described *S. buffalonis* infecting water buffaloes. In Egypt, no reports elucidate the ultrastructure of *S. buffalonis*. Herein, we examined the Egyptian water buffaloes for the presence of *S. buffalonis*, and studying their ultrastructure for the first time. Tissue samples were collected from 550 water buffaloes slaughtered at Mansoura abattoir, Egypt, and examined macroscopically, histologically and ultrastructurally. *S. buffalonis* cysts were noted in 8.72% out of the examined specimens. The prevalence of infection was higher in aged animals than in younger ones. Esophagus was the highly affected tissue followed by throat muscles and diaphragm, while no cysts were detected in the heart or tongue. Morphologically, the cyst wall was thick (3.5-7 μm) and palisade like with conical villar protrusions (3.8-7 μm in length) which bent laterally at an angle nearly 45° on the sarcocyst surface. Villar protrusions were constricted at the base (0.2-0.5 μm wide), expanded laterally in the middle region (0.5-1.0 μm wide), and tapered in the distal end. Bradyzoites measured 8-10.5 μm long and 0.5-1.5 μm wide.

Keywords: *Sarcocystis buffalonis*., Water buffalo., Egypt., ultrastructure.

INTRODUCTION

Sarcocystosis is a widespread protozoan infection in wild and domestic herbivores. The parasite has a two-host life cycle with the sexual stages occurring in carnivorous animals which become infected by ingesting infected meat. Sporocysts shed in the feces are ingested by intermediate host, usually herbivores, in which sarcocysts are usually located in the muscular tissues (**Tadros and Laarman, 1982**). Out of these *Sarcocystis* species infecting domestic animals, a given species usually infects only one species of intermediate host and uses either felids or canids, but not both, as its definitive host (**Dubey et al., 1989**).

Sarcocystis infection is common in buffaloes worldwide as nearly all adult buffaloes are infected with some *Sarcocystis* species in certain countries as India (**Dubey et al., 1989**). The specimens type of at least four species of *Sarcocystis* have been documented and described in the water buffalo, including two macroscopic species: *S. fusiformis*, commonly occurring in south-east Asia, and *S. buffalonis*, and two microscopic species: *S. levinei* and *S. dubeyi* (**Huong, 1999**).

Few reports concerning the macroscopic *S. buffalonis*, which utilizes cats as a definitive host, were published. It was firstly described by **Huong et al. (1997)** in the Vietnamese water buffaloes. In Egypt, **El-Morsy (2010)** noted *S. buffalonis* cysts in the musculature of water buffaloes, but he didn't describe these cysts ultrastructurally while Hilali et al. (2011) described the ultrastructure of *S. dubeyi* in water buffaloes. Finally El-Seify et al. (2014) described the molecular characterizations of *S. fusiformis* and *S. buffalonis* infecting water buffaloes from Egypt. Herein, we focus on the prevalence and distribution patterns as well as ultrastructure of *S. buffalonis* infecting the Egyptian water buffaloes.

MATERIAL AND METHODS

During one-year study, from July 2009 to June 2010, 550 slaughtered water buffaloes at Mansoura abattoir in Dakahlia Province, Egypt, were inspected grossly for the presence of *S. buffalonis* cysts. Tissue specimens from esophagus, tongue, heart, throat muscles and the diaphragm were collected. From each slaughtered animal, two samples (1 cm²) each were obtained. The first sample were fixed in neutral-buffered formalin 10% and processed for standard histological technique (**Bancroft and Stevens, 1996**), while the second one was cut into many pieces at the size of pin head and fixed in cold gluteraldehyde 2.5%. For transmission electron microscopy, the corresponding part to the positive paraffin-embedded sections from 5 recovered cysts, which previously fixed in 2.5 % cold gluteraldehyde, were

post-fixed in 1% osmium tetroxide in phosphate buffered saline, rinsed in the same buffer, dehydrated in ethanol, and embedded in epoxy resin. Then, semi-thin sections were stained with toluidine blue. The ultra-thin sections were contrasted with uranyl acetate and lead citrate (**Dubey et al., 1989**) before examination in a transmission electron microscope (JEOL JEM 1200 EXII) at Faculty of Science, Alexandria University.

RESULTS

S. buffalonis sarcocysts were detected in histological sections of different tissue specimens from 48 (8.72 %) out of 550 slaughtered water buffaloes at Mansoura abattoir, Dakahlia Province, Egypt. The prevalence of infection was higher in aged animals over 5 years old (40 out of examined positive animals) than in younger ones 2-3 years of age (8 out of examined positive animals). Esophagus was found to be the highly affected tissue (89.58%) followed by throat muscles (31.25%) and diaphragm (8.33%), while no cysts were detected in the tongue or heart.

Morphologically, the macroscopic *S. buffalonis* cysts measured 2-10 X 0.5-1.0 mm, and appeared as white threads under the perimysial connective tissue sheet parallel to the longitudinal axis of the muscle fibers. Sometimes the sarcocyst appeared twisted or curved. (**Fig. 1a**).

Histological (**Fig. 1b**) and semithin (**Fig. 1d**) sections showed the sarcocyst wall thick (3.5-7 μm) and radially striated (palisade-like), **Fig. 1c**.

Ultrastructurally, the cyst wall was palisade-like with conical villar protrusions (**Fig. 2a**) which measured 3.8-7 μm in length and bent laterally at angle nearly 45° on the sarcocyst surface. Villar protrusions were constricted at the base (0.2-0.5 μm wide), expanded laterally in the middle region (0.5-1.0 μm wide), and tapered in the distal end (**Fig. 2b**). Numerous hardly course electron-dense granules were scattered between microfilaments which run along the whole villus. The primary cyst wall (PCW) had many undulations may reach up to 50 nm in depth. The ground substance layer was 0.9-1.8 μm thick and harbor few electron-dense granules. Fine septae (0.3-0.8 μm thick) were emanating from the wall dividing the cyst into several compartments packed with metrocytes and bradyzoites.

Metrocytes are not observed probably due to the old age and the senility of the examined cysts. Bradyzoites are typically banana-shaped, measured 8-10.5 μm long and 0.5-1.5 μm wide and enclosed within a double membrane pellicle (PE). Anteriorly, conoid (C) was 250 nm in length, 100 nm base wide and 50 nm apex wide. The micronemes (Mn) were

250-300 in number, they filled the anterior third of the zoite, and 8-10 rhoptries (Rh) were also found. Large (1 μm) and small (0.3 μm) amylopectin granules (Ag) were situated in the middle third and may extend beneath the nucleus which situated posteriorly. Nucleus (N) measured 1-1.5 X 0.5 μm and contain large and small electron dense chromatin granules (Fig. 2c).

DISCUSSION

Few reports conducted the prevalence of the newly described *S. buffalonis* in the water buffalo (*Bubalus bubalis*). Our results showed that 8.72% of the examined animals are infected. The previously recorded prevalences are variable (3% in Iran **Oryan et al., 2010**, 10.5% in Vietnam **Huong et al., 1997**, 13.2% in Egypt **El-Morsy, 2010**, 33% in Vietnam **Huong, 1999**). This variation may be attributed to miss diagnosis during naked eye examination because of its nearly similar shape to *S. fusiformis* cysts in its early stages. Epidemiological and hygienic conditions in different countries are important factors affecting the incidence of *S. buffalonis*.

S. buffalonis cysts were observed in esophagus (89.58%), throat muscles (31.25%), and diaphragm (8.33%), but not found in heart or tongue. These results are in a partial harmony with **Huong et al. (1997)** who found the cysts in abdominal muscles (49%), cervical muscles (44%), esophagus (27%), and was never found in the heart or tongue. **Huong (1999)** demonstrated them in cervical muscles (14.3%), abdominal muscles (16%), tongue (8%) and were never observed in the heart. **Oryan et al. (2010)** found *S. buffalonis* infecting the esophagus and thigh muscles of Iranian buffaloes, while **El-Morsy (2010)** found them in the esophagus which is the only examined organ.

Morphologically, *S. buffalonis* cysts (2-10 X 0.5-1.0 mm) in the present work are comparatively larger than those previously described by **El-Morsy, (2010)**, (1-3 X 0.1-0.5 mm) **Hilali et al. (2011) & Elseify et al. (2014)** from water buffaloes in Egypt, but coincided with **Huong et al. (1997)** in Vietnam (1-8 X 0.1-0.5 mm) and **Oryan et al., 2010** in Iran (1-9 X 0.15-0.6 mm).

Histological sections showed that the sarcocyst had a thick (3.5-7 μm) radially striated wall (palisade like). **Huong et al. (1997)** found that the thickness of the cyst wall was 3-7.7 μm , and **El-Morsy (2010)** noted a relatively thick cyst wall (4-6 μm), while thickness of the cyst wall reported by **Oryan et al. (2010)** was the thinner (2.8-4 μm). The variation of the

thickness of *S. buffalonis* could be attributed to the age of the examined cysts since aged cysts will have thicker wall than younger cysts.

El-Morsy (2010) firstly reported *S. buffalonis* cysts in Egypt but he didn't confirm them ultrastructurally, while **Hilali et al. (2011)** confirmed the structure with electron microscope and **El-Seify et al. (2014)** confirmed the morphology with molecular characterization, while the present work described for the first time the ultrastructure of *S. buffalonis* cysts recovered from the Egyptian water buffaloes (*Bubalus bubalis*). The results of our study are coincided with that reported by **Jhele et al. (2009)** and **Huong et al. (1997)** who firstly reported *S. buffalonis* from Vietnamese water buffaloes. In the present study, VP (7 μm) were palisade like and bent on the surface, while **Huong et al. (1997)** noted that Vp (12 μm) are not bent on the surface. The ground substance (0.9-1.8 μm) in this study is slightly thinner than that noted by **Huong et al., 1997** (1.2-2.8 μm). On the other hand, **Kan and Dissanaiké (1978)** described *S. buffalonis* in the Malaysian water buffaloes as *S. levinei*, and found that the villar protrusions were sloping with irregular highly folded wavy outlines and measured 7.4 μm in length, while the ground substance was 1.9 μm thick. Moreover, the morphological features of the recovered *S. buffalonis* is similar to cattle *S. hirsuta* reported by **Bottner et al., 1987** who stated that the cyst wall was thick projecting a palisade like villar protrusions (3.3-7 μm long) which occluded by microfilaments and rows of coarse electron dense granules.

Comparative ultrastructure of *S. buffalonis* cysts collected from tissues of Vietnamese and Egyptian water buffaloes:

	Vietnam (Huong et al., 1997)	Egypt (present study)
Sarcocyst size	1-8 X 0.1-0.5 mm	2-10 X 0.5-1 mm
Sarcocyst site	Esophagus, diaphragm, and scapular, cervical and abdominal muscles	Esophagus, diaphragm and throat muscles
Cyst wall thickness	3-7.7 μm	3.5-7 μm
Villar protrusions shape	Palisade like not bent on the surface	Palisade like or conical bent on the surface
Villar protrusions length	12 μm	3.8-7 μm
Microfilaments	Present	Present
Electron dense granules	Numerous and coarse	Numerous and coarse
Ground substance thickness	1.2 – 2.8 μm	0.9 – 1.8 μm
Bradyzoites size	10.3-12.0 X 2.6-3.2 μm	8-10.5 X 0.5-1.5 μm

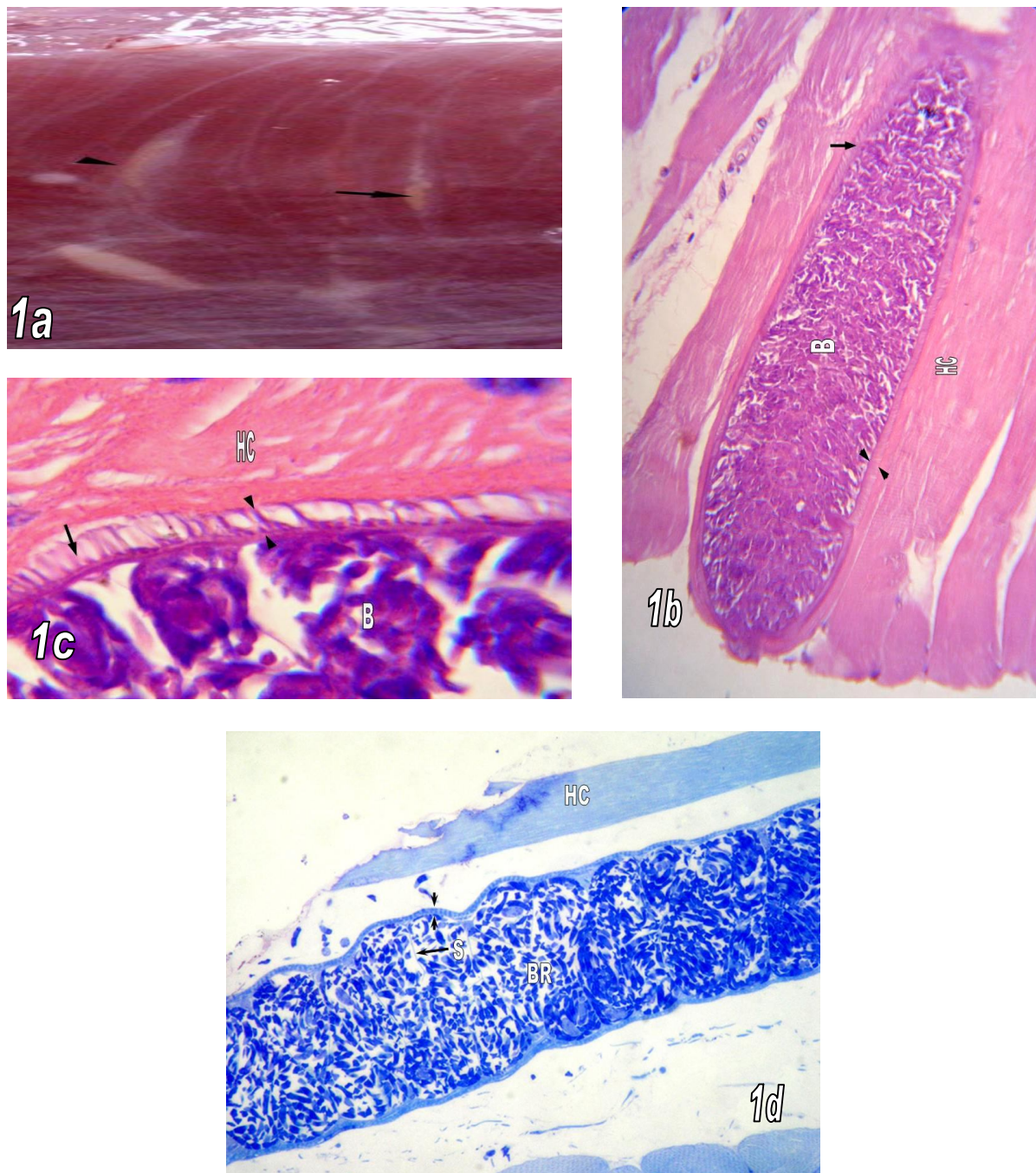


Plate 1: *S. buffalonis* sarcocyst. **a:** macroscopic cyst (arrow) in esophageal muscles appeared as twisted white lines under the connective tissue. **b:** low power view of histological section of the cyst showing the striated thick wall. **c:** high power view showing the thick striated wall (between arrow heads) and conical VP (arrow), host cell (HC), bradyzoites (B). **d:** low power view of semithin section showing the striated cyst wall (between arrow heads), septa (S), bradyzoites (BR) and host cell (HC).

6 - 9 September 2014

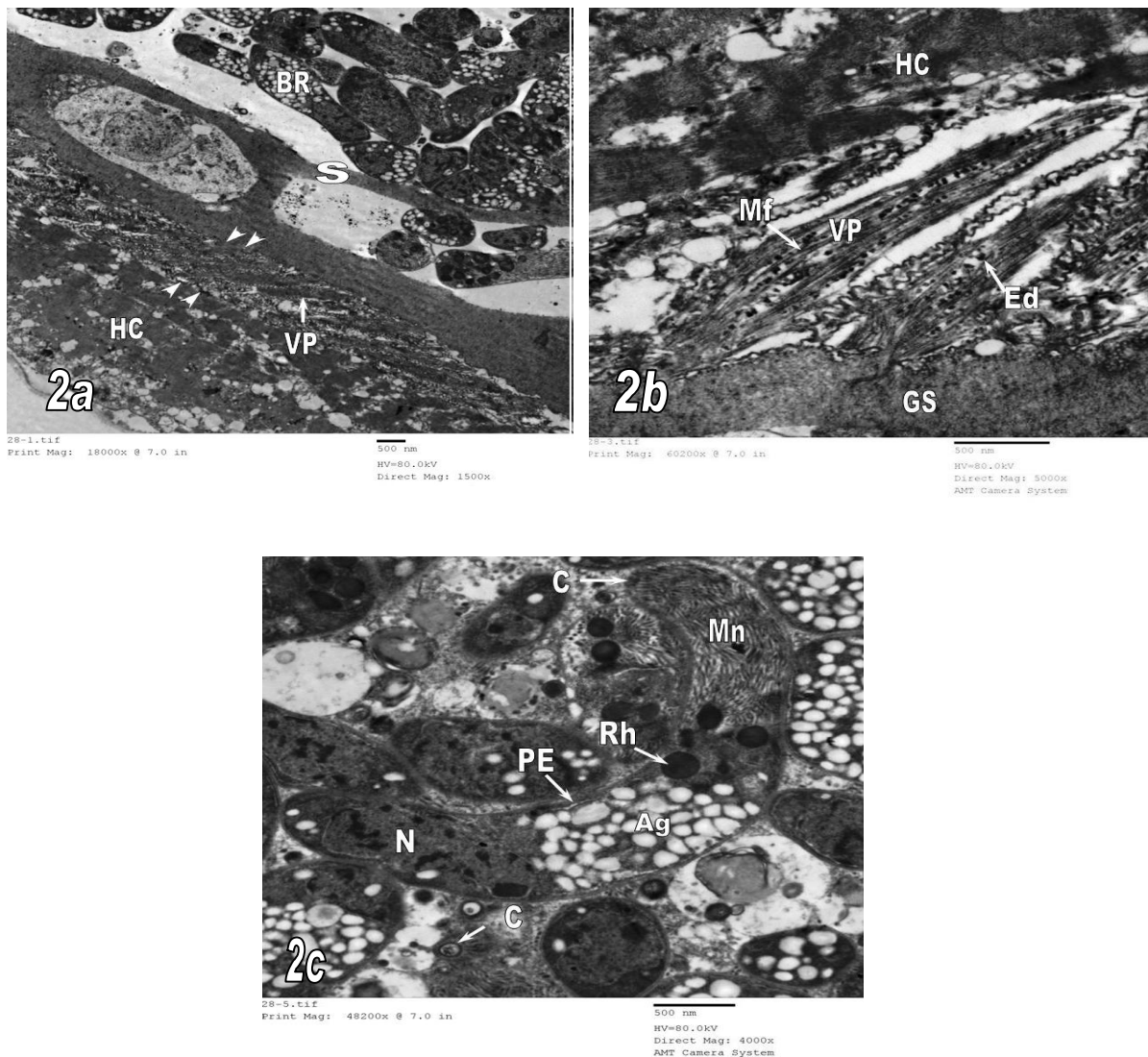


Plate 2: TEM picture of *S. buffalonis* cysts. a: the thick cyst wall (between arrow heads) projecting palisade like villar protrusions (VP) bending on the sarcocyst surface by 45°. Note the Septa (S), bradyzoites (BR) and the host cell (HC). Scale bar = 500 nm. **b:** palisade like villar protrusions (VP) with constricted base (large arrow), laterally expanded mid region (small arrow) and tapered tips (arrow head) bending on the sarcocyst surface by 45°. Note the microfilaments (Mf), course electron dense granules (Ed), ground substance (GS), and the host cell (HC). Scale bar = 500 nm. **c:** banana-shaped bradyzoite. Note the double membrane pellicle (PE), conoid (C), micronemes (Mn) and rhoptries (Rh) in the anterior third, amylopectin granules (Ag) in the middle region and the posteriorly located nucleus (N). Scale bar = 500 nm.

REFERENCES

- Bancroft, J. D. and Stevens, A. (1996):** Theory and practice of histological technique. 4th Ed. Churchill, Livingston, Edinburgh, London, Melbourne and New York.
- Bottner, A., Charleston, W. A. G. and Hopcroft, D. (1987):** The structure and identity of macroscopically visible *Sarcocystis* in cattle. *Vet. Parasitol.*, 24: 35-45.
- Dubey, J. P., Speer, C. A. and Fayer, R. (1989):** Sarcocystosis of animals and man. CRC press, Boca raton, Florida.
- El-Morsy, A. M. (2010):** Studies on *Sarcocystis* species infecting water buffaloes in Egypt. Unpublished M. V. Sc. Thesis, Fac. Vet. Med., Kafrelsheikh Univ.
- El-Seify, M., El-Morsy, A., Hilali, M., Zayed, A., El-Dakhly, Kh., Haridy, M., Sakai, H. and Yanai. T. (2014):** Molecular characterization of *Sarcocystis* *Fusiformis* and *Sarcocystis* *buffalonis* infecting Water buffaloes (*Bubalus bubalus*) from Egypt. *American Journal of Animal and Veterinary Sciences*, 9 (2): 95-104.
- Hilali, M., El-Seify, M., Zayed, A., El-Morsy, A. and Dubey, J. P. (2011):** *Sarcocystis* *dubeyi* (Huong and Uggla, 1999) infection in Water Buffaloes (*Bubalus bubalus*) from Egypt. *J. Parasitol.*, 97 (3): 527-528.
- Huong, L. T. T. (1999):** Prevalence of *Sarcocystis* spp. in water buffaloes in Vietnam. *Vet. Parasitol.*, 86 (1): 33-39.
- Huong, L. T. T., Dubey, J. P., Nikkila, T. and Uggla, A. (1997):** *Sarcocystis buffalonis* n. sp. (Protozoa: Sarcocystidae) from the water buffalo (*Bubalus bubalis*) in Vietnam. *J. Parasitol.*, 83 (3): 471-474.
- Jehle, C., Dinkel, A., Sander, A., Morent, M., Romig, T., Luc, P. V., De, T. V., Thai, V. V. and Mackenstedt, U. (2009):** Diagnosis of *Sarcocystis* spp. In cattle (*Bos taurus*) and water buffalo (*Bubalus bubalis*) in Northern Vietnam. *Vet. Parasitol.*, 166: 314-320.
- Kan, S. P. and Dissanaik, A. S. (1978):** Studies on *Sarcocystis* in Malaysia. II. Comparative ultrastructure of the cyst wall and zoites of *Sarcocystis levinei* and *Sarcocystis fusiformis* from the water buffalo, *Bubalus bubalis*. *Z. Parasitenkd.*, 57: 107-116.

- Oryan, A., Ahmadi, N. and Mousavi, S. M. (2010):** Prevalence, biology and distribution pattern of *Sarcocystis* infection in water buffalo (*Bubalus bubalis*) in Iran. Trop. Anim. Hlth. Prod., 42 (7), 1513-8.
- Tadros, W. and Laarman, J. J. (1982):** Current concepts on the biology, evaluation and taxonomy of tissue cyst forming eimeriid coccidia. Advances in Parasitology, 20: 293-468.

المخلص العربى التركيب الدقيق للمتكيسات العضلية من النوع بافالونز التي تصيب الجاموس فى مصر

صلاح احمد ابوالوفا ، ابراهيم السيد عبدالقادر عباس و مصطفى عبدالسلام العربى

قسم الطفليات- كلية الطب البيطرى – جامعة المنصورة

يصاب الجاموس المصرى باربعة انواع من الساركوسيستس ، منهم نوعان يمكن رؤيتهم بالعين المجردة وهما ساركوسيستس فيوزيفورمس و ساركوسيستس بافالونز و نوعان مجهريان و هما ساركوسيستس ليفينى و ساركوسيستس دويباى. هناك القليل من الدراسات عن ساركوسيستس بافالونز التي تصيب الجاموس. و فى مصر لا يوجد دراسات سابقة تصف التركيب الدقيق لها. و قد اجريت هذه الدراسة لمعرفة مدى انتشار ساركوسيستس بافالونز فى الجاموس ودراسة التركيب الدقيق لها. تم اخذ عينات من انسجة ٥٥٠ جاموسة تم ذبحها بمجزر المنصورة بمدينة المنصورة – مصر و تم فحص هذه الانسجة بالعين المجردة و ميكروسكوبيا و بواسطة الميكروسكوب الالكترونى . و قد وجدت حويصلات ساركوسيستس بافالونز فى ٨,٧٢% من العينات و قد لوحظ زيادة نسبة الاصابة فى الحيوانات كبيرة السن عن الحيوانات الصغيرة. و قد كان المرئ اكثر الانسجة اصابة ثم عضلات الزور ثم الحجاب الحاجز بينما لم توجد اى اصابة بالقلب او اللسان. و بفحص الحويصلات النسيجية لساركوسيستس بافالونز تبين ان الجدار سميك و يتراوح من ٣,٥-٧ ميكرون فى السمك مع وجود بروزات زغبية جرفية الشكل مع انحناء جهة الخارج بزاوية ٤٥ . و قد وجد ان هذه الزوائد ضيقه من جهة القاعدة (٠,٢ – ٠,٥ ميكرون) و متسعة فى المنتصف (٠,٥ – ١ ميكرون) ثم تنتهى مسحوبة. و قد وجد ان المقوسات تصل الى ٨,٥-١٠,٥ ميكرون فى الطول و ٠,٥ الى ١,٥ ميكرون فى العرض.

الكلمات الدالة: ساركوسيستس – بافالونز- الجاموس- مصر.